

Acute Abdomen with Hemoperitoneum: A Rare Presentation Caused by The Rupture of Ovarian Granulosa Juvenile Cell Tumor

Hamillour B*

Public Hospital Establishment, Meghlaoui Brothers Hospital,
Department of Surgery, Mila, Algeria.

*Correspondence:

HAMILLOUR Bochra, Public hospital establishment - Meghlaoui
Mila -Algeria.

Received: 29 May 2019; Accepted: 21 June 2019

Citation: Hamillour B. Acute Abdomen with Hemoperitoneum: A Rare Presentation Caused by The Rupture of Ovarian Granulosa Juvenile Cell Tumor. Surg Res. 2019; 1(1): 1-3.

ABSTRACT

Granulosa juvenile cell tumors are rare neoplasms occur the most often before 20 years with a maximum of frequency between 0 and 10 years, in 44% of cases. These are rare tumors, less than 5% of ovarian tumors of the child and the teenager. 90% of these tumors are usually diagnosed at the stage 1 of the FIGO classification with a favourable prognosis. The presenting symptoms are usually nonspecific with abdominal pain or distension. Acute abdomen due to spontaneous rupture of (JGCT) is extremely rare clinical condition particularly in otherwise healthy subjects.

We report a case of acute abdomen in a young girl due to spontaneous rupture of ovarian tumor. The patient was taken up for emergency; laparotomy drainage of hemoperitoneum and left salpingo-oophorectomy was done.

Keywords

Acute abdomen, Juvenile Granulosa Tumor, Ovarian Tumor, Child, Surgery.

Introduction

Ovarian juvenile granulosa cells are rare; only 0.1% of all ovarian tumors I infants. Their prognosis is predominantly favourable. Hemoperitoneum occurring as a result of spontaneous rupture of the ovarian tumor is a rare complication that is potentially life-threatening in the immediate future.

Observation

A 12-year-old girl was brought to our emergency department with severe right lower abdominal pain. There was no history of abdominal trauma in the past, or any other chronic illness. The patient who was menarchic for two weeks she attained menarche 12 days back with normal menstrual flow. She presented with tachycardia; hypotension; Glasgow coma scale 15, with abdominal distension for three months ago.

Physical examination revealed abdominal tenderness and acute abdomen. Patient looked with normal weight, was dehydrated and pallor was present. Her vitals were pulse rate 120 bpm, blood pressure 90/60 mmHg, respiratory rate 28/min, SpO2 98%, and

temperature 38.2°C. Pelvic examination revealed nearly 15 cm pelvic mass on the right adnexal region. Her hemoglobin count was 9 gr/dl. Hemostatic resuscitation has been used successfully in our patient. After obtaining stable vital signs, abdominal ultrasound and pelviabdominal tomography examination confirmed the mass in the right adnexa measuring 13 × 12 × 8 cm without septations, and also revealed free fluid at Morisson's space and the cul-de-sac (Figure 1, Figure 2).

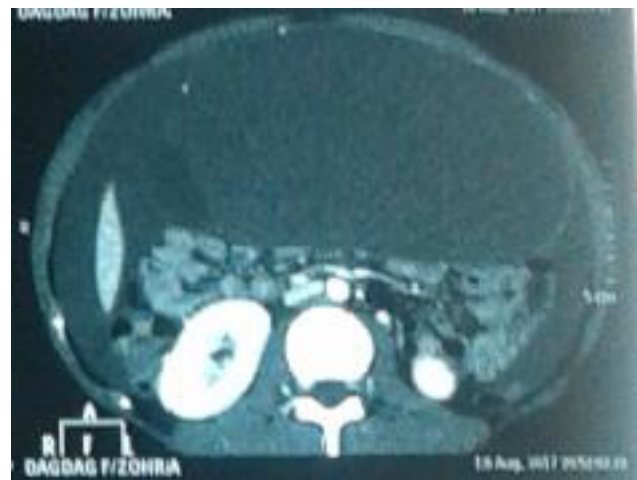

Figure 1: CT (axial view) revealed a large tumor in the entire abdomen and showed without septum in the cystic tumor.

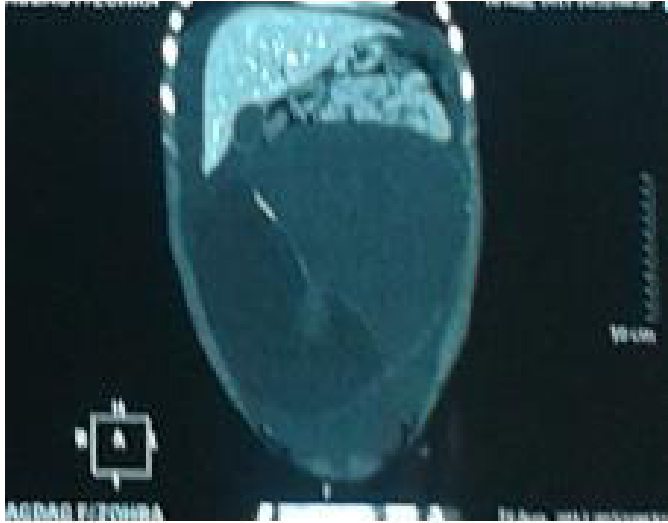

Figure 2: CT (coronal view) of the abdomen and pelvis showing cystic mass and hemoperitoneum.

Because of the clinical findings and 1 gr/dl hemoglobin fall in three hours, an immediate exploratory laparotomy was performed.

During laparotomy large mass arising from right ovary was observed, 2700 cc of blood, ruptured and actively bleeding. Omentum, the left ovary, and the uterus were normal, and right salpingo-oophorectomy was performed in emergency conditions (Figure 3, Figure 4).




Figure 3: 2700 cc of blood, from cyst bleeding.

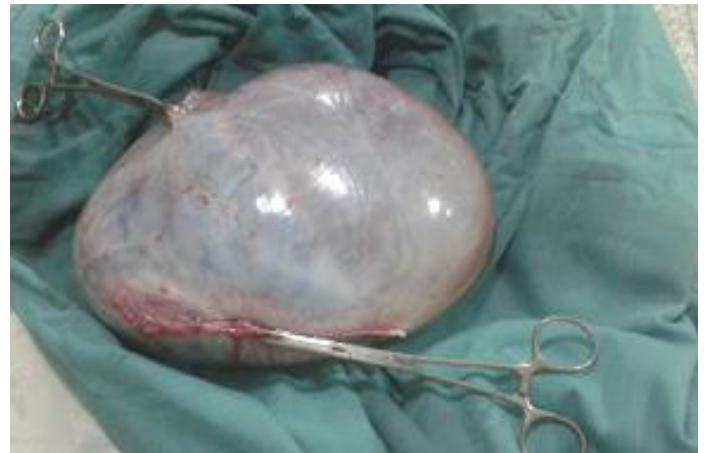

Figure 4: Laparotomy specimen showing right ovarian cystic mass.

Postoperative recovery was uneventful and at follow up one year after surgery the patient was completely asymptomatic. Histology confirmed the diagnosis of ovarian juvenile granulosa cells cystic, evaluated as granulosa cell tumor at least stage 1, no chemotherapy was given.

Discussion

In 1855 Rokitansky presented a first description of juvenile ovarian granulosa tumor (JGCT). It has been established with correlation of morphological aspect of cells tumor, close to that of the granulosa cells of the ovarian follicle [1] They belong to the group of tumors (the mesenchyme and the sexual cord), represent more than 70% of the malignant tumors of this group and 5% of the ovarian cancers [1,2]. The incidence of this tumor is estimated at 1.3 per year per 100,000 females [1-3]. We distinguish two different anatomoclinical entities: the forms adults are more frequent, accounting for 95% of case; they occur during the peri- and postmenopausal period, with a frequency spike around 50 to 55 years [2,3]. The juvenile form is much rarer representing 5% of these tumors; it occurs in women young people under 30 or pre-pubertal [3,4].

The most common form is that of the adult, accounting for nearly 95% of granulosa cell tumors. They are usually present in women over 40 years old in contrast, less than 5% of tumors are of the juvenile [1-3].

Tumors of juvenile granulosa is rarely seen or isolated because it is often found in a syndromic setting in association with other pathological such as Olliers endochondromatosis, Maffucci syndrome and dysplastic abnormalities [5].

Cellular and molecular alterations are involved in the development of JGCT, this hypothesis has been supported in the literature. On the light of chineses study; Wen-Chung Wang and Yen-Chuin Lai juvenil-type granulosa cell tumors are associated with FOXL2 402C > G mutation. In addition to this unique FOXL2 mutation, they found DNA replication error and loss of heterozygosity. DNA mismatch repair system failure can be detected likely in these patients [6].

Symptoms are usually nonspecific with different clinical presentation such as chronic abdominal pain, an abdominal mass, or distension. In rare cases symptoms related to hyperestrogenism in prepubertal age group, precocious puberty with breast development increased pubic hair, vaginal bleeding [1-4]. Acute abdomen is a rare presentation of JGCT. Till now, very few cases have been reported [7-10].

Occasionally, JGCT rupture causes abdominal pain and hemoperitoneum. It is usually associated with a mass on pelvic examination which is subsequently confirmed with imaging techniques [6].

Biological diagnosis is actually can be performed with inhibin alpha-subunit which can be elevated in 87 % showed a rise in inhibin levels preceded clinical recurrence as early as 20 months. However not all tumors express inhibin as a marker [6].

Radiological diagnosis based on the ultrasound and scan, the juvenile granulosa cell tumor appears generally as an important ovarian mass, cystic, solid or mixed tumor the echogenic content aspect of it [4]. The ovarian walls are related to the occurrence of bleeding. In our case, the patient presented with acute pain abdomen and an abdominal mass and was similarly taken up for emergency laparotomy.

Crystalloid solutions and blood transfusions are the mainstays in-hospital treatment of severe haemorrhagic shock, after TJGC rupture. Resuscitation with massive transfusion protocols above control of the source of bleeding as soon as possible [9,10].

The goal of surgical management in JGCT is twofold, first preservation of fertility and radical excision of the tumor. The recommended surgical includes salpingo-oophorectomy remains the treatment of choice [4,7,8,10].

According to Takeda and Al, less tumorectomy followed by adjuvant chemotherapy could be a feasible management option in young patients with strong desire for ovarian preservation, however this approach cannot be applied in emergency situation [11].

Chemotherapy is reserved only for recidivism its principle is the same as that in invasive cancer, to remove the whole of the disease that is macroscopically visible. The tumors of the juvenile granulosa are classified according to FIGO's usual staging and they correspond to stage one with a favourable prognosis [8,11].

Conclusion

In addition to its rarity in childhood, the presented case is of particular interest for having abdominal pain and distension only

without any secondary sexual characteristics; we conclude that it is very important to sensitize the population toward the early consultation in cases of young girls with an abdominal mass and pain abdomen. This is necessary to pick up ovarian tumors. Surgery is the mainstay of initial management for histological diagnosis, appropriate staging, and debulking at initial stages so that prompt therapy can be instituted and the prognosis can be improved in these patients.

References

1. Lazrak. Granulosa-cell tumor of the ovary. International Journal of Innovation and Applied Studies. 2014; 7: 1020-1024.
2. Park JY, Jin KL, Kim DY, et al. Surgical staging and adjuvant chemotherapy in the management of patients with adult granulosa cell tumors of the ovary. Gynecol Oncol. 2012; 125: 80-86.
3. S Ellouze, S krichen-Makni, K Trabelsi, et al. Granulosa-cell tumor of the ovary: report of 16 cases. Journal de Gynécologie Obstétrique et Biologie de la Reproduction. 2007; 35: 767-772.
4. Kristin R. Rusterholz, William MacDonald. An Unusual Case of Juvenile Granulosa Cell Tumor of the Ovary. Radiol Case Rep. 2016; 4: 178.
5. Behiye Pinar, Cilesiz Goksedef, safak Yilmaz Baran, et al. Juvenil granulosa cell in a woman with Maffucci syndrome the eldest cases in literature. 2012.
6. Wen-Chung Wang, Yen-Chein Lai. Molecular pathogenesis in granulosa cell tumor is not only due to somatic FOXL2 mutation. journal of ovarian research J Ovarian Res. 2014; 7: 88.
7. Evans AT 3rd, Gaffey TA, Malkasian GD Jr, et al. Clinicopathologic review of 118 granulosa and 82 theca cell tumors. Obstet Gynecol. 1980; 55: 231-238.
8. Fox H, Agrawal K, Langley FA. A clinicopathologic study of 92 cases of granulosa cell tumor of the ovary with special reference to the factors influencing prognosis. Cancer. 1975; 35: 231-415.
9. Fettman MJ. Hypertonic crystalloid solutions for treating hemorrhagic shock. Compend Contin Educ Pract Vet. 1985; 7: 915-920.
10. Leder RR, Lane VM, Barrett DP. Ovariectomy as treatment for granulosa cell tumor in a heifer. J Am Vet Med Assoc. 1988; 9: 1299-1300.
11. Jang NR, Lee DH, Jang EJ, et al. Ovarian Gynandroblastoma with a Juvenile Granulosa Cell Tumor Component in a Postmenopausal Woman: A Case Report and Literature Review. J Pathol Transl Med. 2018; 52: 344-348.