

Epidemiological, Clinical, Therapeutic and Evolutionary Aspects of Corneal Abscesses at the Teaching Hospital of Bouaké (Côte d'Ivoire)

Ouattara Y¹, Diabaté Z¹, Godé LE¹, Koffi KFH¹, Tembely Y², Babayeju ORL¹, Sékongo L¹, Bilé PEFK¹, Diomandé GF¹ and Diomandé IA¹

¹Ophthalmology Department of the Teaching Hospital of Bouaké, Ivory Coast.

²Investigator; Ophthalmology Department of the Teaching Hospital of Bouaké, Ivory Coast.

*Correspondence:

Dr Yves Ouattara, Ophthalmology Department of the Teaching Hospital of Bouaké, 01 BP 1130 Bouaké 01, GSM : 00 225 0757787747.

Received: 15 September 2021; **Accepted:** 10 October 2021

Citation: Ouattara Y, Diabaté Z, Godé LE, et al. Epidemiological, Clinical, Therapeutic and Evolutionary Aspects of Corneal Abscesses at the Teaching Hospital of Bouaké (Côte d'Ivoire). *Ophthalmol Res.* 2021; 4(1); 1-6.

ABSTRACT

Introduction: The purpose of this study was to describe the epidemiological, clinical, therapeutic and evolutionary aspects of corneal abscesses treated in the ophthalmology department at the Teaching Hospital of Bouaké, in order to contribute to an improvement in their management.

Materials and methods: A longitudinal retrospective study based on the analysis of medical records of patients with corneal abscesses who received follow-up in the department. from 1 January 2012 to 31 December 2016 and 21 cases of unilateral abscesses were collected from a total of 18,585 cases.

Results: The frequency of corneal abscesses was 0.11%. The average age of patients was 27.71 years (1-year and 73-year extremes) with a male predominance (1.1 sex ratio). Housewives and farmers accounted for 57.14%. Patients were admitted more than 7 days after the onset of signs in 33.33% of cases. At admission, the visual acuity of the affected eye was less than 1/20 in 16 patients (76.19%) and among them, 6 had no light perception. The abscess was localized to the left eye in 11 patients (52.38%). Its largest diameter was greater than 2 millimetres in 14 patients (66.66%), its seat was in the visual axis in 10 patients (47.61%) and in 12 patients (57.14%), its depth exceeded two-thirds of the corneal thickness. Corneal perforation was observed in 6 cases (28.57%) and severity factors were found in 19 patients (90.47%).

No microbiological examination was performed and treatment was based on probabilistic antibiotic therapy. The cure was achieved but at the cost of anatomical sequelae whose functional consequences were visual acuity less than 1/20 in 76.19% of cases.

Conclusion: corneal abscesses are infrequent but very serious with poor prognosis in our conditions. This prognosis can be improved by early and adequate management, including microbiology-guided antibiotic therapy.

Keywords

Corneal abscess, Ivory Coast, Keratitis, Treatment.

Introduction

Corneal abscess is the proliferation of microorganisms in the corneal tissue, associated with tissue destruction secondary

to inflammation and infection. It is a serious pathology that is potentially blinding despite considerable therapeutic progress. Risk factors for corneal abscesses include trauma, contact lens wear, ocular surface pathology, history of eye surgery, and immunosuppressive conditions.

Germ penetration typically requires a defect in the integrity of the corneal epithelium, but some germs can penetrate the corneal epithelium without prior damage.

In emerging and developing countries, severe corneal abscesses are considered a major cause of blindness and most often result in trauma. In developed countries, the bacterial origin is believed to be prominent due to the increasing use of contact lenses [1].

In French-speaking sub saharan Africa, 30% of people with visual impairments are said to be visually impaired because of corneal injuries that could have been prevented or are still available for treatment [2]. The prevalence of corneal abscesses is constantly increasing and varies across countries. The impact of corneal abscesses on the prevalence of blindness is due to the corneal scars they leave as sequelae. These have an estimated contribution of about 70% among causes of blindness in African children [3]. Indeed, under treatment, the evolution of the corneal abscess can lead to the sterilization of the corneal infectious hearth. However, healing processes aimed at repairing tissue damage caused by infection, may leave scars more or less opaque altering the transparency of the cornea. The functional impact of these corneal scars then depends on their locations, densities and extent. These scars are very poor functional prognosis in a context such as ours, where corneal transplants, which are almost routine in industrialized countries, are rarely performed [4]. In addition, tissue destruction subsequent to microbial proliferation may be complicated by a deep extension of the infection leading to intraocular tissue destruction or perforation of the eyeball with, resulting in anatomical and functional loss of the eye.

The positive diagnosis of corneal abscess is generally easy. It is most often evoked in front of a painful red eye with a decrease in visual acuity and confirmed by biomicroscope examination. But its clinical aspects remain polymorphic and sometimes misleading. As for its etiological diagnosis, it is essentially microbiological thus requiring quality equipment and infrastructure. If probabilistic antibiotic therapy is used for emergency treatment, this treatment should be rapidly guided by the identification of the germ involved and the completion of an antibiogram [5]. This requires close collaboration between the ophthalmologist and the biologist.

Would corneal abscesses have any particularities in our context where the conditions for this collaboration between ophthalmologist and biologist are rarely met?

The purpose of our study is to describe the different epidemiological, clinical, therapeutic and evolutionary aspects of corneal abscesses admitted and treated in the ophthalmology department of the Teaching Hospital of Bouaké

Material and Methods

This is a longitudinal retrospective study that covered a period of 05 years (January 1, 2012 to December 31, 2016). It was based on the analysis of medical records of patients with corneal abscesses diagnosed treated and followed at the ophthalmology department of

the Teaching Hospital of Bouaké. Files with sufficient information to inform the survey form were systematically included in the study. Out of 18,585 files, 21 files were retained, representing 21 eyes. And the following data were collected:

Sociodemographic data: age, gender, type of activity;

History: the date of onset of symptoms ‘in order to determine the duration of the consultation), the treatments received before admission.

The data of the clinical examination: the distance visual acuity measured on the decimal scales of Monnoyer for the literate and that of Snellen for the non-literate, the seat of the abscess in relation to the visual axis, its size, its depth and the associated signs;

Data from microbiological examinations,

Therapeutic data: therapeutic means and international nonproprietary names (INN) of medicinal products and their routes of administration;

Clinical evolution data: visual acuity and clinical aspects of the cornea and eye.

The quantitative data were averaged and standard deviations were calculated. As the study is descriptive, no statistical test was conducted.

Results

After analysis of 18,585 files, 21 cases of corneal abscess were identified, ie a frequency of 0.11%.

The average age of the patients was 27.71 years with extremes of 1 year and 73 years. In addition, the age group 45 to 60 was the most affected with 6 cases, 28.57%. It was followed by those aged 0 to 15 and 15 to 30, each with a total of 5 cases or 23.81%. Only one case was noted in the 30 to 45 age group, or 4.76%.

Male predominance was low at 52.38%, a sex ratio of 1.1.

Housewives and agricultural actors accounted for 57.14% (n=12) in our series (Table 1).

Table 1: Distribution of patients by occupation.

Occupation	Total	Percentage
Housewives	7	33,33
Worker / craftsman	3	14,29
Cultivator / peasant / herder / farmer	5	23,81
Pupil / student	4	19,05
Trader	1	4,76
Without activity *	1	4,76
Total	21	100,00%

Housewives and agricultural stakeholders (farmers, farmers, herders and farmers) accounted for 57.14% of the sample.

Without activity* : infant

The patients who had consulted more than 7 days after the onset of the first symptoms represented 33.33% (Figure 1).

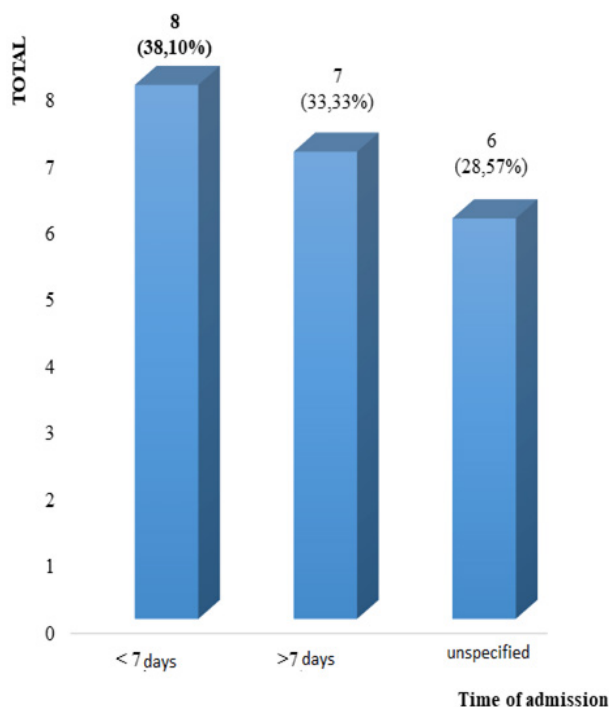


Figure 1: Distribution of Patients by Consultation Time After Onset of Symptoms.

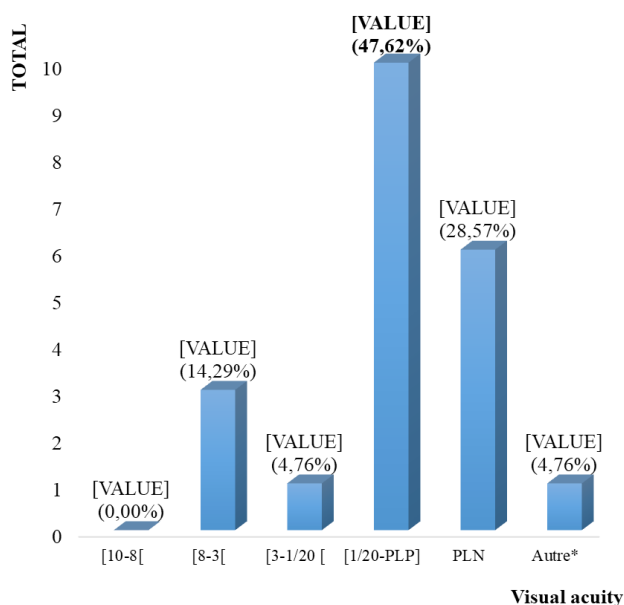


Figure 2: Distribution of patients according to the visual acuity value of the affected eye on admission.

PLP = positive light perception

NLN = negative light perception

Other*: This was a 1-year-old infant whose visual acuity could not be determined.

Eye pain was the most frequently reported functional sign in 66.66% of cases, followed by redness of the eye and loss of visual acuity in proportions of 38.10% and 33.33%, respectively.

In 9.52% of cases purulent secretions were reported. A notion of ocular trauma preceding the onset of symptoms was found in 7 patients (33.33%). There were 16 (76.19%) patients who had not been treated before admission. In contrast, 4 patients (19.05%) reported pre-intake management. For 2 of them it was a self-medication based on gentamycin in eye drops for one patient and based on an unidentified eye drops for the other. For the other 2, one had been treated in an ophthalmology department and the other had instead used traditional treatment. In one patient, this notion of treatment before admission had not been specified.

On examination, the initial visual acuity was less than or equal to 1/20 in 16 eyes, or 76.19%. (Figure 2).

For the abscess, it was localized to the right eye in 10 patients (47.76%) and to the left eye in 11 patients (52.38%). Its large axis had a diameter greater than 2 millimetres in 14 patients (66.66%), its seat was in the visual axis in 10 patients (47.61%) and in 12 patients (57.14%), its depth exceeded two-thirds of the corneal thickness. Corneal perforation was observed in 4 cases (19.05%) and severity factors were found in 19 patients (90.47%).

No patient had performed a microbiological examination and the anti-infectious treatment was carried out on an outpatient basis, “blind” both locally and generally.

In terms of local treatment, all patients received a combination of fluoroquinolone and aminoglycoside in local treatment. In 18 patients (85.71%) it was ciprofloxacin + tobramycin and in 3 patients (14.28%) ciprofloxacin was associated with gentamicin. Associated with this treatment, 7 patients (33.33%) had received injections under conjunctival gentamicin for 3 days, at the beginning of treatment. In one patient (4.76%) hexamidine eye drops had been associated and no patient had received antifungal treatment. Overall treatment was based on a combination of imidazole (Metronidazole) and fluoroquinolone (Ciprofloxacin) in 10 patients (47.61%) and in 2 patients (9.52%), Metronidazole was associated with beta-lactamase (Amoxicillin + clavulanic acid). Five patients (23.80%) had mono-antibiotic therapy with fluoroquinolones (Ciprofloxacin) and 4 patients (19.04%) had no general antibiotic therapy.

After «cooling», a patient had been eviscerated for a corneal puncture from the ocular contents.

The evolution was marked by healing with significant sequelae. In 11 patients (52.38%) the sequelae were of the type of central (10) and para-central (1) corneal nebula with a significant functional impact. In 6 patients (28.57%), there was an anatomical loss of the eyeball and in 4 patients (19.04%), the sequelae were of the type of peripheral corneal nebula with a low functional impact (Table 2).

At the end of the evolution, the distance visual acuity was less than 1/20 for 16 eyes (76.19%), as on admission.

Table 2: Distribution of patients according to the course of the disease.

Evolution		Total	Percentages
Healing after anatomical and functional loss of the eye	Perforation + evisceration	1	4,76%
	Perforation with purulent mass of the eyeball	4	19,05%
Healing with loss of eye function	Perforation + adherent leukoma	1	4,76%
Healing with significant anatomical and functional sequelae	Central nebula type sequela	10	47,62%
	Para-central nebula type sequela	1	4,76%
Healing with anatomical sequelae but low functional impact	Peripheral nebula type sequela	4	19,05%
Total		21	100%

In the majority of cases the healing was achieved but with significant anatomical and functional sequelae (80.95%).

Discussion

socio-demographic characteristics

Prevalence: The corneal abscess represents a pathology whose incidence varies from country to country. It is 11 per 100,000 people per year in the United States and can reach 799 per 100,000 people per year in Nepal [6]. In France, according to Bourcier, corneal abscesses represent 5,000 cases of consultation each year and the increase has been 400% in recent years due to the use of contact lenses [7]. Its incidence remains unknown in our context. In our series, the frequency of corneal abscess was 0.11%. This data tells us about the extent of this pathology, but also about its disparity since there is a higher incidence in developing countries than in developed countries, especially the United States.

Gender: In our series, with a rate of 52.38%, men had slightly more corneal abscesses than women (M/F sex ratio of 1.1). This male predominance is also found in several authors such as Keay in Australia [8], Pamar [9] and Ancele in France [10]. However, other authors highlighted a slight predominance of the female sex in particular, in Tunisia with a sex-ratio of 0.75 [11], in England with a sex-ratio of 0.83 [12] and in the Netherlands, a sex-ratio of 0.74 [13]. These data discrepancies appear to confirm that sex is not a risk factor for corneal abscess.

Age: Corneal abscesses can occur at any age of life. The patients in our study are characterized by an average age of 27.71 years while the literature indicates that the average age of occurrence of corneal abscesses is higher. Indeed, according to TJ Norina in Malaysia, the average age was 44.5 years [14] and other authors found an even higher average age of occurrence. This is the case of Baklouti K in Tunisia, Van der Meulen in the Netherlands and Ancele in France, who find respectively average ages of 59.2 years, 58 years and 50 years [10,11,13]. This discrepancy of our data with the literature could be indicative of an epidemiological particularity of corneal abscesses in our conditions. Further work could investigate the determinants of such a feature.

Occupation: Housewives had the highest proportion of the sample, with a frequency of 33.33% followed by those in the agricultural sector with a frequency of 23.81%. These two occupations alone accounted for more than half of the total, or a frequency of 57.14%. This could be explained by the fact that these people are constantly exposed to corneal trauma in the practice of their profession, especially among actors in the agricultural sector. In addition, the high frequency observed in housewives could be

explained by exposure to heat and smoke from traditional type kitchens. These working conditions, which promote dry eyes and almost permanent eye irritation, could weaken the surface of the eye and promote corneal abscesses. In summary, these activities could be considered at-risk activities for the occurrence of corneal abscesses due to their high frequencies in the sample.

Clinical and paraclinical aspects

Consultation period: The average consultation time varies between 14 and 26 days, according to the authors. This period varies according to the risk factors, it is 3 days in contact lens wearers, 8 days in case of anterior segment surgery and 9.3 days in case of ocular surface pathology [15,16]. In our series the average delay could not be calculated due to cases whose symptomatology start date could not be specified, however the patients who consulted after 7 days accounted for 33.33% of the sample. Indeed, this relatively long consultation period can be explained by previous treatments performed by some patients. Moreover, housewives who are probably accustomed to the signs of eye irritation due to their working environment, as well as those in the agricultural sector who are accustomed to the frequent projection of dust and particles in the eyes, may have neglected the functional signs beginning of the affection.

Functional symptoms: In our series, pain is the first indicator of corneal abscess at 66.66%, followed by a decrease in visual acuity in 7 patients (33.33%). These findings are inconsistent with those of the various studies that reported redness of the eye as the primary symptom of corneal involvement [17, 18]. This finding in our conditions must make suspect corneal abscess in any subject presenting with eye pain with a decrease in visual acuity, especially if he is performing a risky activity.

Visual acuity: The majority of patients in our series had a visual acuity of less than 1/20, both at admission and at the end of evolution, with a frequency of 76.19%, of which 28.57% had a light perception absent. If these patients had only these eyes with abscesses, they would be blinded. These data show the severity of corneal abscesses in our conditions, despite their apparent rarity.

Abscess characteristics: The size of the abscess greater than 2 mm in diameter in the majority of cases (66.67%), its position on the visual axis in almost half of cases (47.62%) and its depth beyond the 2/3 anterior corneal thickness in more than half of cases (57.14%). These data show that these abscesses had local criteria

of severity [19] and poor functional prognosis already at intake. This is illustrated by the corneal perforation observed in 6 patients.

Microbiological examination: In our series no microbiological examination was carried out. According to the literature, the positive rate of corneal cultures varies between 60% and 84% [20-22].

The relative frequency of the different germs responsible for corneal abscesses varies greatly from one region to another and depends on geographical location and climate. In warm and humid regions, fungal abscesses and *Pseudomonas* are more common while the prevalence of staphylococcus and streptococcal abscesses increases in cold climate regions [23,24]. According to the series, bacterial abscesses are the most common (up to 78.4%), with a predominance of Gram+. Fungal abscesses occupy the second place [25,26].

Failure to carry out microbiological examinations under our conditions constitutes an obstacle to the identification of the microbiological profile of corneal abscesses and thus negatively influences the quality of their management.

Therapeutic and evolutionary aspects

Treatment: The therapeutic management of serious abscesses requires hospitalization with the initiation of antibiotic therapy in synergistic combination active on Gram+ and Gram-, effective and non-toxic dosages for the cornea and then adapted to the results of microbiological sampling. The topical route is the preferred route, the parenteral route being indicated only if there is a risk of spreading the infection in depth or during preperforative states, endophthalmitis or scleritis. The use of local corticosteroids is a controversial topic in the treatment of infectious keratitis: they are of great use to reduce the extent of stromal scars and iris synechias.

In our series, the treatment was outpatient and made of Fluoroquinolones in eye drops, alone or combined with other antibiotics in all patients with a therapeutic success marked by sterilization of the infectious home in 100% of cases. Due to the lack of microbiological testing, antifungals were not prescribed.

Does the low reporting of previous treatments really reflect the reality or would the frequency of these treatments have been undervalued? Indeed, Ouattara and al stressed the tendency of patients to ignore this kind of treatment because of a sense of guilt and fear of being reprimanded by medical staff [27].

Evolution: Factors of poor prognosis of corneal abscesses are delayed diagnosis, pre-existing surface pathologies, prior treatment with corticosteroids, resistance to treatment, presence of hypopyon, onset of perforation and immunocompromised courses. The prognosis is particularly bleak when it is a mycobacterial abscess or keratomycosis [28-31].

In our study the surgery known as evisceration was performed in a single patient for perforation with ocular content. In 4 other

cases the perforation left as sequelae a phtysia of the eyeball. The other patients presented nebula type sequelae, adherent leukoma. In total the abscesses caused the anatomical and functional loss of 5 eyeballs (23.81%) and left sequelae to functional consequences such that 16 eyes (76.19%) were in a state of blindness.

These data show that the corneal abscess remains a serious pathology and poor prognosis in our conditions. Factors of poor prognosis could be the delay in consultation, possible prior treatment by self-medication (including traditherapy), outpatient management despite the existence of severity factor. In addition to these factors it should be noted that the failure to perform microbiological examinations does not allow a targeted treatment against the germ in question.

Conclusion

From our study it appears that the corneal abscess remains a rare but serious pathology in our hospital practices. It is a pathology of the young adult most often affecting the actors of the agricultural sector and the housewives with a slight male predominance. On admission to a specialized environment the majority of abscesses had criteria of gravity and their evolution under outpatient treatment was characterized by sterilization of infectious outbreaks. However, this healing took place at the cost of sequelae responsible for monocular blindness in the majority of cases.

Improving the prognosis of corneal abscesses requires an extension of eye health care and the strengthening of the technical platform of hospitals for early and adequate management. Conducting microbiological examinations in case of corneal abscesses is strongly recommended for a better adaptation of the treatment. The public should be made aware of the use of eye protection in the event of activities with a high risk of eye trauma on the one hand and early consultation in front of any redness of the eye accompanied by pain and decreased visual acuity.

References

1. Erie JC, Nevitt MP, Hodge DO, et al. Incidence of ulcerative keratitis in defined population from 1950 through 1988. *Arch ophthalmol.* 1993; 111: 1665-1671.
2. Auzemery A, Négril AD. Cécité et baisses de vision au Sud du Sahara, un problème de santé publique. *EMC, Ophtalmologie.* 2002; 21-591-A-10: 2.
3. Foster A, Sommers A. Childhood blindness from corneal ulceration in Africa: causes, prevention and treatment. *Bull WHO.* 1986; 64: 619-623.
4. Ouattara Y, Koffi KV, Kouassi FX, et al. La greffe de cornée à l'hôpital militaire d'Abidjan : à propos de six cas. *Revue Africaine de chirurgie.* 2007; 10: 35-38.
5. Ritterband, David. *Ophtalmologie en urgence.* paris : Elsevier Masson : 2016.
6. Boutkhil C. Les ulcères de cornée. Université Sidi Mohamed Ben Abdellah. Faculté de Médecine et de Pharmacie Fès. 2010: 114.

7. Bourcier T, Thomas F, Borderie V, et al. Bacterial keratitis : predisposing factors, clinical and microbiological review of 300 cases. *Br Ophthalmol.* 2003; 87: 834-838.
8. Keay L, Edwards K, Naduvilath T, et al. Microbial keratitis : predisposing factors and morbidity. *Ophthalmology.* 2006; 113: 109-116.
9. Pamar P, Salman A, Kalavathy CM, et al. Microbial keratitis at extremes of age. *Cornea.* 2006; 25: 153-158.
10. Ancele E, Lequeux L, Fournie P, et al. Severe bacterial keratitis. A clinical, epidemiologic, and microbiologic study. *J Fr Ophthalmol.* 2009; 32: 558-565.
11. Baklouti K, Ayachi M, Mhiri N, et al. Les abcès cornéens présumés d'origine bactérienne. *Bull. Soc. Belge ophtalmol.* 2007; 305: 39-44.
12. Ibrahim YW, Boase DL, Cree IA. Epidemiological characteristics, predisposing factors and microbiological profiles of infectious corneal ulcers: the Portsmouth corneal ulcer study. *Br ophthalmol.* 2009; 93: 1319-1324.
13. Van Der Meulen IJ, Van Rooij, Nieuwendaal CP, et al. Age-related risk factors, culture outcomes, and prognosis in patients admitted with infectious keratitis to two dutch tertiary referral centers. *Cornea.* 2008; 27: 539-544.
14. Norina T J, Raihan S, Bakiah S, et al. Microbial keratitis : aetiological diagnosis and clinical features in patients admitted to hospital university Sains Malaysia. *Singapore. Med J.* 2008; 49: 67-71.
15. Ouaggag B, Jellab B, Moussaoui K, et al. Abcès graves de la cornée: difficultés diagnostiques et thérapeutiques à Marrakech. *J Fr Ophthalmol.* 2009; 32: 125.
16. Darugar A, Gaujoux T, Goldschmidt P, et al. Clinical, microbiological and therapeutic features of severe bacterial keratitis. *J Fr Ophthalmol.* 2011; 34: 362-368.
17. McDonnel PJ. Empirical or culture-guided therapy for microbial keratitis? A plea for data. *Arch Ophthalmol.* 1996; 114: 84-87.
18. Frederic Chiambaretta, Frederic P, Daniele R. Cornée: méthodes d'examen et sémiologie. *Encycl Med Chir.* 2001.
19. Polycopié national du collège des ophtalmologistes universitaires de France. *Kératites. SFO,* 2008-2009.
20. Boro.A. Aspects épidémiocliniques des kératites au centre de sante de Reference de la commune v du District de Bamako : These med : Univ de Bamako. 2014: 09.
21. Limaïem R, Mghaieth F. Les abcès graves de la cornée: à propos de 100 cas. *J Fr Ophthalmol.* 2007; 30: 374-379.
22. Rodman RC, Spisak S. The utility of culturing corneal ulcers in a tertiary referral center versus a general ophthalmology clinic. *Ophthalmology.* 1997; 104: 1897-1993.
23. Kerautret J, Raobela L. Kératites bactériennes sévères: étude rétrospective clinique et microbiologique. *J Fr Ophthalmol.* 2006; 29: 883-888.
24. Whal JC, Katz HR. Infectious keratitis in Baltimore. *Ann Ophthalmol.* 1991; 23: 234-237.
25. Chien-Fan F, Chia-Hui T. Clinical characteristics of microbial keratitis in a university hospital in Taiwan. *Am J Ophthalmol.* 1983; 15: 834-836.
26. Carmichael TR, Wolpert M. Corneal ulceration at an Urban African Hospital. *Br J Ophthalmol.* 1985; 69: 920-926.
27. Ouattara Y, Koffi KV, Safédé K, et al. Traitement de la cataracte par les tradipraticiens : Methodes et complications à propos de 30 malades. *J.sci.pharm, boïl.* 2007; 41-50.
28. Fong CF, Tseng CH, Hu FR, et al. clinical characteristics of microbial keratitis in a university hospital in Tauwain. *Am j ophthalmol.* 2004; 137: 329-336.
29. Wanh JC, Su D, Lim L. contact lens microbial keratis and prior topical steroid use: a disaster in the making? *Ann Acad Med Singarore.* 2004; 33: 484-488.
30. Morlet N, Minassian D, Butcher J. Risk factors for treatment outcome of suspected microbial keratidis. *J Br ophthalmol.* 1999; 83: 1027-1031.
31. Killingsworth DW, Stern GA, Driebe WT, et al. Results of therapeutic penetrating Keratoplasty. *Ophthalmology.* 1993; 100: 34-41.