

Microangiopathic Hemolytic Anemia Associated with Preeclampsia

Dra. Rosa María Torres Hernández¹, Dra. Beatriz González Jiménez¹, Dra. Rocío del Carmen Honorato Rodríguez¹, Dr. Humberto Hernández Ojeda², Dra Nayali López Balderas³ and Vianey Cobaxin Honorato⁴

¹Department of Clinical Research UV-CA-477 Universidad Veracruzana.

²Department of Gynecology and Obstetrics Hospital de Alta Especialidad SSA.

³Institute of Forensic Medicine UV.

⁴School of Medicine Student.

*Correspondence:

Torres Hernández Rosa María, Mercurio 19. Fraccionamiento Jardines de Mocambo, Boca del Rio Veracruz, Mexico, CP 94299, Tel. 52+2299014903.

Received: 29 Oct 2021; Accepted: 30 Dec 2021; Published: 05 Jan 2022

Citation: Torres HRM, Gonzalez JB, Honorato RR, et al. Microangiopathic Hemolytic Anemia Associated with Preeclampsia. Int J Biomed Res Prac. 2022; 2(1); 1-4.

ABSTRACT

Introduction: Preeclampsia is the most common hypertensive disease of pregnancy which can be developed during the second half of pregnancy. Among its symptoms, there might be high blood pressure, edema, headache, visual symptoms to name a few. Whereas in laboratory studies it is usually found as data of pre-eclampsia; microangiopathic hemolytic anemia, platelet deficiency and urine protein.

Objective: To determine the association of microangiopathic hemolytic anemia with preeclampsia.

Material and Methods: Longitudinal, prospective and observational study in patients through laboratory tests such as blood biometry, blood smear and general urine test, and blood pressure measurement, as well as the review of clinical files in order to get the patients' symptomatology.

Results: Among the results, it was found that 63% of the pregnant participants with pre-eclampsia suffered from microangiopathic hemolytic anemia, 54% of them were primiparous and 46% were multiparous. Edema, headache, abdominal pain, transvaginal bleeding and visual issues were the most common symptoms, resulting either in termination of pregnancy or continuity of it with the corresponding hypertensive control.

Conclusions: The association between microangiopathic hemolytic anemia and preeclampsia as a complication of pregnancy.

Keywords

Microangiopathic hemolytic anemia, Preeclampsia, Schistocytes.

Introduction

Preeclampsia is a disorder which may appear during the second half of pregnancy. It is currently one of the most important factors to consider, since its presence increases the chances of complications or maternal-fetal death considerably [1]. This affects approximately 15% of pregnancies and represents nearly 18% of all maternal deaths in the world, with an estimated 62,000 to 77,000 per year. The symptoms presented are arterial hypertension, edema,

headache, visual problems, tinnitus, nausea, dizziness, abdominal pain, transvaginal bleeding, seizures, hyperreflexia and HELLP syndrome. Due to the severity of some of them, the only definitive treatment is the termination of pregnancy. Despite the fact, there is no specific cause of preeclampsia known, it is acknowledged that vasoconstriction of small vessels produced during pregnancy is one of the triggers of this disease [2].

Preeclampsia is a disorder presented as multisystemic, whose clinical parameters are gestational age higher than 20 weeks of gestation, blood pressure higher than 140/90 mmHg, having a low

platelet count less than 100 000, elevation of transaminases twice as high as normal values, increase in serum creatinine from 1.1 mg/dL, presence of pulmonary edema or emergence of brain and visual alterations [3-5].

The vasoconstriction, that can develop pre-eclampsia, results in the appearance of microangiopathic hemolytic anemia, because of the vasoconstriction in small vessels, hemolysis is caused by the accumulation of fibrin and tissue factor. Meshes are created because of the accumulation of fibrin, so the erythrocytes are broken when they pass through them, and these along with the fibrin micro thrombi decrease more the caliber of the vessels, causing tissue damage and decreased blood flow.

Microangiopathic hemolytic anemia is the one that happens when there is some injury or cause that alters circulatory dynamics, such as vasoconstriction, accumulation of micro-thrombi and the formation of fibrin meshes [3].

Damage to small vessels such as capillaries and arterioles can be the cause of a type of hemolytic anemia known as microangiopathic anemia. The mechanism of hemolysis is always due to the erythrocytes rupture in the microcirculation, as a result of the shearing forces generated by blood pressure when acting on a vascular lumen partially obstructed by platelet deposits and micro-thrombi, or an endothelium injured with deposits in its interior. Microangiopathic hemolytic anemia is caused by the destruction of erythrocytes, because of the physical cut drifted from their way through occluded vessels due to systemic micro-thrombi [12]. The interaction of erythrocytes with these injuries leads to their fragmentation, conducting the emergence of a relatively generalized and intense intravascular hemolysis, with the clear presence of circulating schistocytes. This guides to the platelets consumption, secondary to the formation of microthrombi which results in the intense thrombocytopenia factor found in this disease.

The study aimed to determine the association of microangiopathic hemolytic anemia with preeclampsia.

Material and Methods

A cross-sectional, prospective, observational and comparative study was carried out in 94 patients. 59 of them were suffering from preeclampsia and microangiopathic hemolytic anemia at the Dr. Bernardo Peña General Hospital in San Andrés Tuxtla, with prior authorization from the local research committee and informed consent. Inclusion criteria: pregnant women with preeclampsia; exclusion: patients with a diagnosis of pre-eclampsia and who had a urinary tract infection. Patients with preeclampsia were divided into two groups: primiparous and multiparous. When women were admitted to the hospital, medical records, laboratory tests of venous blood sample through a vacutainer for blood biometry, and a blood smear via understanding blood on a slide method were taken, then it was found the presence of schistocytes. Transvaginal bleeding, abdominal pain, and visual symptoms were measured. Tachycardia, edema, headache.

Statistical analysis with means and standard deviation as a measure of central tendency and dispersion. Student's t test for independent samples of the signs and symptoms data of the primiparous and multiparous patients. It was used the Pearson χ^2 statistical test with the Statistica Version 6.0 program, to evaluate the relationship between anemia and eclampsia, with statistically significant differences with the value of $p < 0.05$. The association of the variables, anemia and eclampsia in the primiparous and multiparous patients the Relative Risk was calculated since it is a cross-sectional study (RR), for a risk assessment.

Results

The age of the primiparous patients was 22.55 ± 4.14 years and the multiparous 29.15 ± 1.06 . The weeks of gestation: first pregnancy 22.03 ± 1.92 , multiparous 27.03 ± 3.92 . Diastolic and systolic blood pressure in first pregnancy 128.6 ± 10.2 and 186.02 ± 4.0 mmHg.

Multiparous patient $124.82 \pm 12.1^*$ and 172.92 ± 8.0 mmHg. (Table 1) ($p < 0.05$) Diagnosis of hospital admission during this study: transvaginal bleeding: primiparous 30 (66%) and multiparous 35 (71%); abdominal pain: primiparous 32 (71%), multiparous 35 (71%); finally visual symptoms: primiparous 17 (38%) and multiparous 12 (25%) (Figure 1).

Signs and symptoms presented by the patients when admission; edema: primiparous 27 (60%) and multiparous 20 (40%). Headache: primiparous 35 (77%) and multiparous 30 (61%); abdominal pain: primiparous 32 (71%) and multiparous 35 (71%); visual symptoms: primiparous 17 (37%) and multiparous 12 (24%). Bleeding: primiparous 30 (66%) and multiparous 35 (71%) (Table 2) ($p < 0.05$).

The development of microangiopathic hemolytic anemia was observed in 54% of primiparous patients, while it was presented in 46% of multiparous.

The results of the patients of the two groups with preeclampsia and without it were analyzed in relation to or without Microangiopathic anemia with schistocyte (Figure 2) in primiparous and multiparous. (Table 3). An association was found between primiparous patients and microangiopathic anemia ($p < 0.05$) and the risk was higher for the primiparous patient (RR = 1.3 $p = 0.0386$, 95% CI 0.9151-1.934).

Table 1: Patients' symptoms with microangiopathic hemolytic anemia associated with preeclampsia.

	Primiparous n = 51	Multiparous n = 49
Age	22.55 ± 4.14	29.15 ± 1.06*
Gestation weeks	22.03 ± 1.92	27.03 ± 3.92
Distolic blood pressure (mmHg)	128.6 ± 10.2	124.82 ± 12.1*
Systolic blood pressure (mmHg)	186.02 ± 4.0	172.92 ± 8.0*
Heart rate (heartbeats x min)	90.83 ± 6.77	98.02 ± 4.8

Student's t test for independent samples ($p < 0.05$)

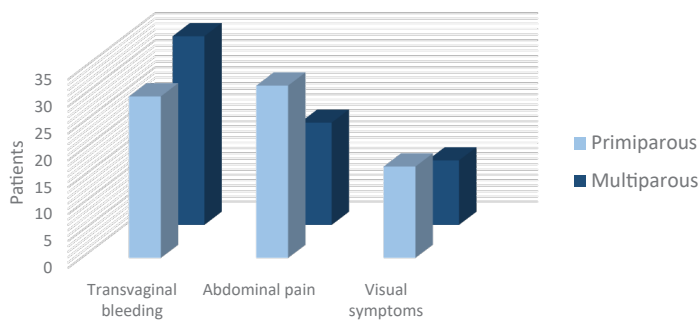


Figure 1: Hospital admission diagnosis in patients with microangiopathic hemolytic Anemia associated with preeclampsia.

Table 2: Patients' symptoms with microangiopathic hemolytic anemia associated with preeclampsia.

Symptoms	Primiparous (n = 51)	Multiparous (n = 49)	P
Edema	27 (60%)	20 (40%)	0.05
Headache	35 (77%)	30 (61%)	0.01
Abdominal pain	35 (71%)	32 (65%)	NS
Visual symptoms	17 (37%)	12 (24%)	0.05
Bleeding	30 (66%)	35 (71%)	0.01
Thrombocytopenia	49 (96%)	40 (73%)	
Proteinuria	42 (82%)	36 (73%)	

*x² of Pearson (p<0.05) significant.

Table 3: Microangiopathic hemolytic anemia associated with preeclampsia in primiparous and multiparous.

Microangiopathic anemia	With preeclampsia N (%)	Without preeclampsia N (%)	X ²	p
Primiparous				
With anemia	35(79%)	3 (43%)	4.28	0.05*
Without anemia	9 (21%)	4 (57%)		
Total	44 (100%)	7 (100%)		
Multiparous				
With anemia	30 (78%)	6 (54%)	2.61	1.065
Without anemia	8(22%)	5(46%)		
Total	38(100)	11 (100%)		

*x² of Pearson (p<0.05) significant.

In pre-eclampsia, the development of injuries in capillaries and arterioles is caused by the hemolytic type anemia known as microangiopathic. The mechanism of hemolysis attributable to the erythrocytes rupture in the microcirculation, because of the blood pressure increase that acts on a vascular lumen partially obstructed by platelet deposits and microthrombi [12].

Preeclampsia is a disorder associated with gestational age longer than 20 weeks, with blood pressure higher than 140/90 mm Hg, dipstick with 1+ protein in urine sample. The diagnosis could be settled when gestational arterial hypertension, nausea or vomit, in addition to thrombocytopenia presence with alterations in liver enzymes¹. It was found proteinuria, diastolic and systolic blood pressure with a significant rise in both groups, predominantly in the primiparous patient.

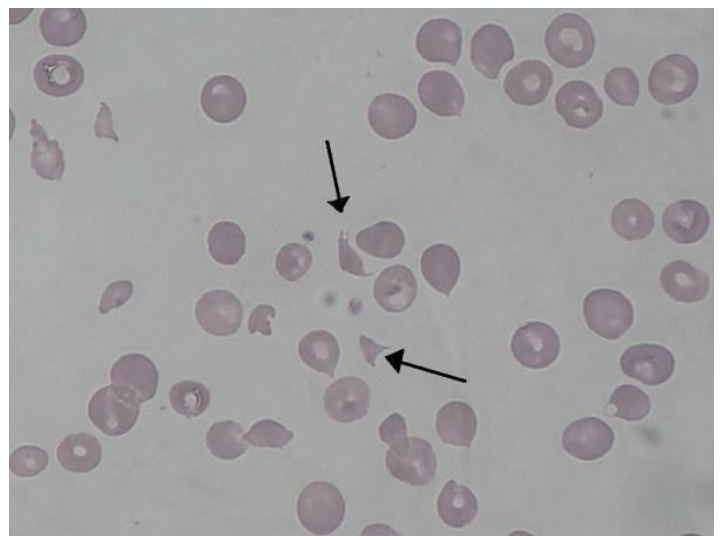

Figure 2: Blood smear from peripheral blood smear with clear presence of schistocytes.

Preeclampsia is more common in primiparous patients since multiparous patients with preeclampsia backgrounds develop an adjustment mechanism to vascular, endothelial, immune, and cardiac changes during pregnancy. Preeclampsia is related to maternal factors such as placental, they can be abnormalities that happen in the early stages of the placental microcirculation development, which cause relative hypoperfusion, hypoxia and even ischemia. These lead to the release of anti-angiogenic factors in the maternal circulation that modify maternal endothelial function, bringing on hypertension and other typical manifestations of the disease [3-5]. In our research, a lower proportion of multiparous women presented preeclampsia as previously described.

It was found that from 74 pregnant patients with pre-eclampsia and microangiopathic hemolytic anemia, 51% of them were primiparous. The presence of pro-inflammatory cytokines responsible for vascular endothelial dysfunction and increased inflammatory responses must be considered; these are factors associated with hypertension, thrombotic microangiopathy that can sometimes lead to hemolysis, elevated liver enzymes and syndrome of low platelet count or HELLP syndrome, with edema and pulmonary or brain problems [6-9]. Pregnant women with preeclampsia symptomatology there was microangiopathic hemolytic anemia, hypertension, edema, headache and visual symptoms.

The interaction of erythrocytes with these injuries conducts to their fragmentation, resulting in the emergence of a relatively generalized and intense intravascular hemolysis, with clear presence of circulating schistocytes. This directs to the consumption of platelets secondary to the formation of microthrombi having the factor of intense thrombocytopenia as an outcome found in this disease [13-15].

The most frequent complication is microangiopathic hemolytic

anemia with schistocytes, thrombocytopenia and coagulation disorders [13,16,17]. In this study, it was found that 63% of patients had schistocytes in blood smears [16]. Arterioles narrowing and constriction along with endothelial cell swelling probably contributes to mechanical destruction of the red blood cell. 79% of the patients in this study had proteinuria, 64% thrombocytopenia, and 47% edema.

References

1. Prevención diagnóstico y tratamiento de preeclampsia en el segundo nivel de atención. Guía de práctica clínica. IMSS. 2017.
2. Ukah UV, Payne B, Cotè AM, et al. Risk Factors and predictors of pre-eclampsia. En The FIGO Textbook of Pregnancy Hypertension, London. 2015: 75-101.
3. Gathiram J Moodley. Pre-eclampsia: its pathogenesis and pathophysiology. Cardiovascular Journal of Africa. 2016; 27: 71-76.
4. Uzan J, Carbonnel M, Piconne O, et al. Pre-eclampsia: pathophysiology, diagnosis and management. Vasc Health Risk Manag. 2011; 7: 467-474.
5. Luis M Gómez. Actualización en la fisiopatología de la preeclampsia. Revista Peruana de Ginecología y Obstetricia. 2014; 60: 321-327.
6. García S, Costales B, Jimeno J.M. Physiopathology and etiopathogenic factors of arterial hypertension in pregnancy. Toko-ginecología práctica. 2000; 59: 194-212.
7. Danilo N. Mendez. New interpretations in the classification and diagnosis of pre-eclampsia. En revista MEDISA. 2016; 20.
8. De Gracia VP. Síndrome HELLP. Ginecol Obstet Mex. 2015; 83: 48-57.
9. Abildgaard U, Heimdal K. Patogenia del síndrome de hemólisis, enzimas hepáticas elevadas y recuento bajo de plaquetas (HELLP): una revisión. Eur J Obstet Gynecol Reprod Biol. 2013; 166: 117-123.
10. Sarabia ES, Diaz JE, Garcia MV. Preeclampsia severa, eclampsia, síndrome de HELLP, comportamiento clínico. Rev Fac Med UNAM. 2005; 48: 145-50.
11. Lina BBadimon, Jose M. Gonzales. Disfunción endotelial. Rev Esp Cardiol Supl. 2006; 6: 21A-30A.
12. Penninton AK, Schlitt JM, Jackson DL, et al. Preeclampsia: multiple approaches for a multifactorial disease. Dis Model Mech. 2012; 5: 9-18.
13. Duley L. Pre-eclampsia and the hypertensive disorder of pregnancy. Br Med Bull. 2003; 67: 161-76.
14. Contreras E, De la Rubia J, Garma J, et al. Diagnostic and Therapeutic guidelines of thrombotic microangiopathies. Medicina clínica. 2015; 144: 331.
15. Douglas BC, Levine DL. Thrombocytopenia in pregnancy. BLOOD. 2017; 130: 2271-2277.
16. Cunningham FG, Nelson BD. Disseminated Intravascular Coagulation Syndromes in Obstetrics. OBSTETRICS & GYNECOLOGY. 2015; 126: 999-1011.
17. Granfortuna J. The Many Faces of Thrombotic Microangiopathies. J Blood Disord Transfus. 2019; 10: 1-11.