

## Observational Study of Gerdy's Tubercle on Fully Ossified Dry Human Left Tibia

Mahbuba Akter<sup>1\*</sup>, Jubaida Gulshan Ara<sup>2</sup>, Fahmida Zaman<sup>3</sup>, Omma Hafsa Any<sup>4</sup>, Khandaker Nadia Afreen<sup>5</sup> and Khaled Jamil<sup>6</sup>

<sup>1</sup>Associate Professor, Department of Anatomy, Z H Sikder Women's Medical College, Dhaka.

<sup>2</sup>Professor and head, Department of Anatomy, Mugda Medical college, Dhaka.

<sup>3</sup>Associate Professor, Department of Anatomy, MH Samorita Medical College, Dhaka.

<sup>4</sup>Associate Professor, Department of Pharmacology and Therapeutics, Army Medical College, Jashor.

<sup>5</sup>Associate Professor, Department of Physiology, Z H Sikder Women's Medical College, Dhaka.

<sup>6</sup>Assistant Professor, Department of Dentistry, Z H Sikder Women's Medical College, Dhaka.

### \*Correspondence:

Dr. Mahbuba Akter, Associate Professor, Department of Anatomy, Z. H. Sikder Women's Medical College, Dhaka, Tel: +8801850074765.

**Received:** 16 June 2021; **Accepted:** 10 July 2021

**Citation:** Akter M, Ara JG, Zaman F, et al. Observational Study of Gerdy's Tubercle on Fully Ossified Dry Human Left Tibia. Int J Psychiatr Res. 2021; 4(4): 1-4.

### ABSTRACT

**Introduction:** Gerdy's tubercle is a lateral tubercle of the upper end of tibia where the iliotibial tract inserts. The aim of this study is to find out the shape of Gerdy's tubercle on fully ossified dry human left tibia with their clinical association.

**Materials and methods:** The present study is an observational analytic type of study which was performed on of two hundred (200) fully ossified dry human left tibia of unknown sex, conducted in the department of Anatomy, Sir Salimullah Medical College, from July 2014 to June 2015. In this study fully ossified dry human left tibia of unknown sex were collected from the department of Anatomy and also from the students of Sir Salimullah Medical College (SSMC), Dhaka, Ibrahim Medical College (IMC), Dhaka, Dhaka National Medical College (DNMC), Dhaka and Bangladesh Medical College (BMC), Dhaka.

**Results:** The shape is evaluated subjectively and tubercles classified as type A was found in 55.0%, type B in 13.5%, type C in 15.5%, type D in 4%, type E in 9% and type F in 3%. In male Type A was found in 58.2%, Type B in 15.3%, Type C in 12.2%, Type D in 4.1%, Type E in 8.2% and Type F in 2%. In female Type A was found in 52%, Type B in 11.8%, Type C in 8.6%, Type D in 3.9%, Type E in 9.8% and Type F in 3.9%.

**Conclusion:** The different shapes of Gerdy's tubercle demonstrated in the present study may contribute to produce significant effect on surgical interventions and some shapes may be more prone to traumatic injuries on it.

## Keywords

Observational study, Gerdy's tubercle, Fully Ossified.

## Introduction

In human body, tibia is the stronger and second largest bone next to femur and is commonly recognized as the large weight bearing bone of the leg [1]. The fascia lata thickens to form a strong band, the iliotibial tract which is attached to anterolateral facet on the lateral condyle of tibia, known as Gerdy's tubercle. The term tubercle in Gerdy's tubercle is a misnomer. However, it is actually a facet present on upper end of tibia on the anterolateral surface of lateral condyle. Gerdy's tubercle describes it to be located around 1 cm below joint line and 2cm lateral to tibial tuberosity [2]. Gerdy's tubercle is named after French surgeon Pierre Nicolas Gerdy (1797-1856) [3]. This is also important because of attachment of iliotibial band of lateral thigh and usually gets fractured along with tibial tuberosity [4]. These fractures are commonly treated surgically by open reduction and internal fixation. In the present study examination of tibia revealed more than usual variations in the shape of tubercle present at the anterior surface of lateral condyle of tibia. These osseous surfaces are smooth and are being poorly vascularized. Gerdy's tubercle classified as type A, type B, type C, type D, type E and type F. Beneath the condyles is the tibial tuberosity which serves for attachment of patellar ligament a continuation of quadriceps femoris muscle [5].

The importance of Gerdy's tubercle in surgical practice is paramount. It is an important anatomical landmark for many surgical interventions in this region including bone graft or knee replacement surgeries [6]. Is used as a site for the insertion of periosteal needle by which intramedullary fluids may be infused in the neonates [7]. Another study suggested that cancellous bone grafts might be harvested from Gerdy's tubercle on the proximal metaphysis of the tibia for surgical procedures on the upper extremity. Another study demonstrated that the course of the common peroneal nerve related with tubercle it serves as an important landmark which provides sensation and motor function to parts of lower leg [8].

The observational descriptive type of study about tibia have not yet been studied in Bangladesh. In the present study examination of tibia revealed more than usual variations in the shape of tubercle in both male and female. Therefore, information regarding different shape of Gerdy's tubercle provide baseline data for anatomy, planning treatment and diagnostic procedures of orthopaedic surgery, kinesiology and also in physical treatment and rehabilitation [9].

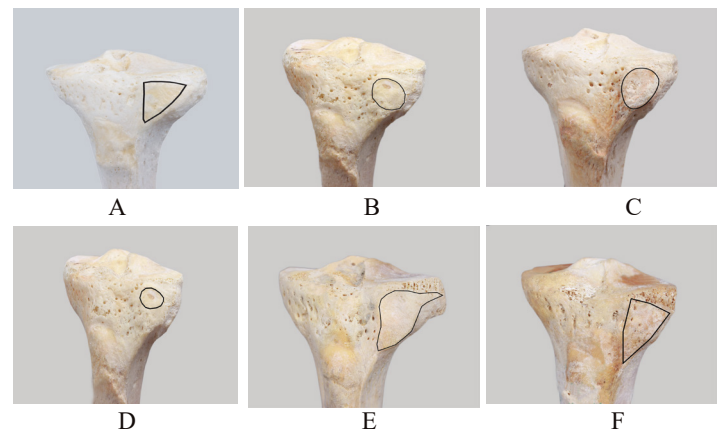
## Materials and Methods

This is an observational descriptive type of study which was carried out in the department of Anatomy of Sir Salimullah Medical College (SSMC), Dhaka from July 2014 to June 2015 performed on two hundred (n=200) fully ossified dry human left tibia. This study was carried out on the samples by direct observational

method as shown in Figure 1.

Depending on texture and shape of Gerdy's tubercle have been described by Rani et al. on 2014 -

- type A -triangular and smooth
- type B- circular and smooth
- type C- vertically oval and smooth
- type D- transversely oval and smooth
- type E- irregular and rough
- type F- triangular and rough



**Figure 1:** Different shapes of Gerdy's tubercle on tibia.

## Ethical clearance

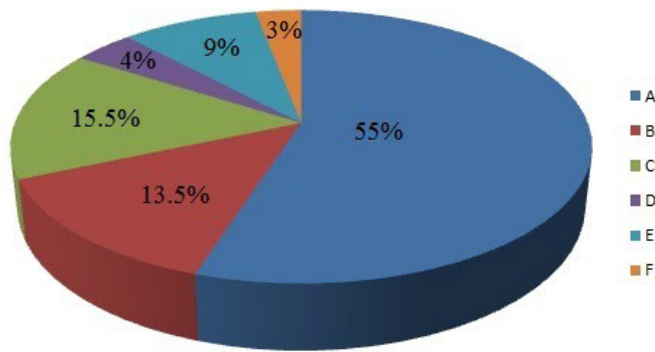
This study was approved by the Institutional Ethics Committee (IEC) of Sir Salimullah Medical College, Dhaka.

## Results

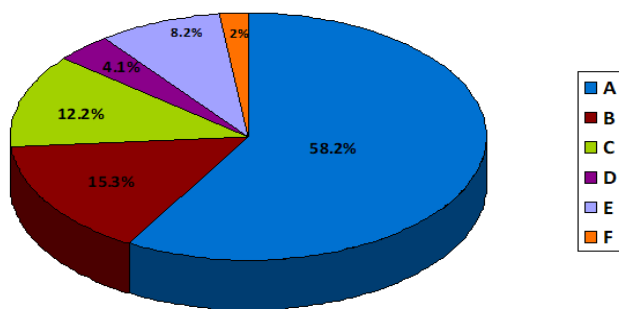
The texture and shape of gerdy's tubercle was highly variable and was wide ranging from a small circular facet to entirely irregular facet both in male and female. In the present study, shape of Gerdy's tubercle type A- was found in 110 cases (55.0%), type B in 27 cases (13.5 %), type C in 31 cases (15.5%), type D in 8 cases (4 %), type E in 18 cases (9 %) and type F in 6 cases (3 %). In male Type A was found in 59 cases (58.2%), Type B in 16 cases (15.3%), Type C in 12 cases (12.2%), Type D in 4 cases (4.1%), Type E in 9 cases (8.2%) and Type F in 2 cases (2%). In female Type A was found in 51 cases (52%), Type B in 11 cases (11.8%), Type C in 18 cases (18.6%), Type D in 4 cases (3.9%), Type E in 10 cases (9.8%) and Type F in 4 cases (3.9%) as shown in Figure 2, Figure 3, Figure 4, Table 1 and Table 2.

**Table 1:** Percentage (%) of different types of Gerdy's tubercle of left tibia.

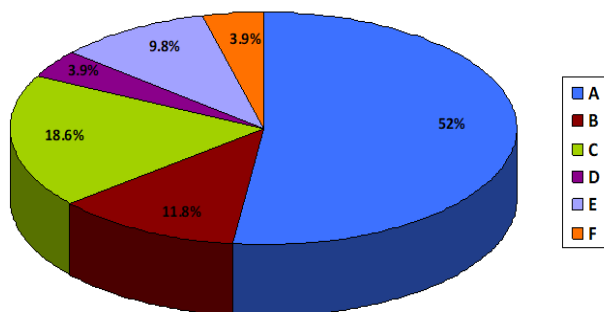
Types	Frequency	Percentage (%)
A	116	58.0
B	27	13.5
C	31	15.5
D	8	4.0
E	18	9.0
Total (n)	200	100.00



**Figure 2:** Pie chart showing percentage (%) of different types of Gerdy's tubercle of left tibia.



**Figure 3:** Pie chart showing percentage (%) of different types of Gerdy's tubercle of left tibia in male.



**Figure 4:** Pie chart showing percentage (%) of different types of Gerdy's tubercle of left tibia in female.

**Table 2:** Types of Gerdy's tubercle of left tibia in male and female.

Types	male		female	
	Frequency	Percentage (%)	Frequency	Percentage (%)
A	59	58.2	51	52.0
B	16	15.3	11	11.8
C	12	12.2	18	18.6
D	4	4.1	4	3.9
E	9	8.2	10	9.8
F	2	2.0	4	3.9
102 100.00 98 100.00				

## Discussion

The present study has demonstrated in excess of usual variations in the shape of Gerdy's tubercle. Different authors have described it to be a different shape but before the study of Rani et al, there was no any previous study has demonstrated its inconsistent shape. Atlas of human anatomy has shown Gerdy's tubercle as transversely oval in one place where as it has demonstrated it to be triangular in other plates [10]. Other studies have described it as a flat but definite marking, which is triangular and facet like on anterior aspect of lateral condyle of tibia but there was no statement of different shapes by them [11]. Some other authors also labeled Gerdy's tubercle as irregular or triangular [12]. The muscles tensor fascia lata and gluteus maximus insert into iliotibial tract, the differential pulls over a long period producing different shapes of Gerdy's tubercle. Rani et al was demonstrated in excess of useful variation in the shape of Gerdy's tubercle on 2013. In the present study majority of bones had a type A tubercle. The findings of the present study were similar to the study reported by Rani et al (110-113) who worked in the Anatomy department, University College of Medical Sciences, Delhi. In their study, they observed the Gerdy's tubercle of 103 tibia and in left found triangular (type -A) in 44.6%, circular (type -B) in 17.4%, vertically oval (type -C) in 2.9%, transversely oval (type -D) in 3.8%, irregular (type -E) in 18.4% and triangular (type -F) in 6.7% of the samples. It is an important anatomical landmark for many surgical interventions in this region including bone graft or knee replacement surgeries. The lateral approach has been described using an oblique incision from Gerdy's tubercle to apex of tibial tuberosity to successfully allow entry through the cortex to harvest cancellous bone avoiding the epiphyseal line [13].

## Conclusion

The different shapes of Gerdy's tubercle demonstrated in the present study may contribute to produce significant effect on surgical interventions and some shapes are more prone to traumatic injuries on it. So, this study might help the anatomist, radiologist and orthopedic surgeon for planning of clinical interventions.

## References

1. Snell RS. Clinical Anatomy by regions. 9th ed. New Delhi: Wolters Kluwer (India) Pvt. Ltd. 2012; 470-471.
2. Drake RL, Vogl AW, Mitchell AWM. Gray's anatomy for students. 2nd ed. Philadelphia: Churchill Livingstone. 2010; 602-627.
3. Wigley C. Gray's anatomy: the anatomical basis of clinical practice. New York: Elsevier Churchill Livingstone. 2005.
4. Starky Chad. Examination of orthopedic and athletic injury. (3rd ed) F.A Davis P218. 2009.
5. Kalra S, Chauhan P, Khandelwal A, et al. Variations of Gerdy's tubercle. Proposal of a morphological classification: Anatomical study and its clinical importance. 2014.
6. Brutus JP, Loftus JB. Gerdy's tubercle as a source of cancellous bone graft for surgery of the upper extremity: description of technique. J Hand Surg Am. 2006; 31: 147-149.

- 
7. Yoo JH, HahnSH, Yang BK. An enbloc avulsion fracture of tibial tuberosity and Gerdy's tubercle in an adolescent basketball player. *Knee surg sports Traumatol Arthrosc.* 2007; 15: 781-785.
  8. Tam M. Nerves of the lower limb. *Medical student's retreat-Micheal tam's anatomy notes for medical students.* 2006; 324-325.
  9. Rubel I F, Schwarzbard I, Leonard A, et al. Anatomic location of the peroneal nerve at the level of the proximal aspect of the tibia Gerdy's safe zone. *The Journal of Bone and Joint Surgery.* 2004; 86: 1625-1628.
  10. Netter FH. *Atlas of human anatomy.* 5th ed. Philadelphia: Saunders. 2011.
  11. Williams PL, Banister LH, Berry MM, et al. *gray's anatomy.* New york: Churchill livingstone. 1995.
  12. Agur AMR, Dalley AF. *Grant's atlas of anatomy.* Baltimore: Lippincott Williams & Wilkins. 2009.
  13. Benninger B, Rossb A, Delamarter T. Approaches to proximal tibial bone harvest techniques. *Journal of Oral & Maxillofacial Research.* 2012.