

Stem Cell Transplantation for HIV-Related Lymphoma

Shannon Smith and Vincent S. Gallicchio*

Department of Biological Sciences and the Honors College, Clemson University, Clemson, SC 29632, USA.

***Correspondence:**

Dr. Vincent S. Gallicchio, Department of Biological Sciences and the Honors College, Clemson University, Clemson, USA.

Received: 21 October 2019; **Accepted:** 17 November 2019

Citation: Shannon Smith, Vincent S. Gallicchio. Stem Cell Transplantation for HIV-Related Lymphoma. Stem Cells Regen Med. 2019; 3(1): 1-7.

ABSTRACT

Blood malignancies in HIV-infected individuals are the number one cause of mortality due to cancer in the HIV community. Thus, the virus is no longer killing people, it is cancer, specifically lymphoma, which is accounting for the majority of mortality cases. The major lymphomas found in HIV-infected individuals include non-Hodgkin's lymphoma, Diffuse Large B Cell lymphoma, Burkitt lymphoma, and Hodgkin's lymphoma. One treatment strategy to treat these malignant diseases is through the use of chemotherapy. Chemotherapy is effective at keeping cancer manageable for this cohort of patients; however, to date it has not demonstrated to be effective at eradicating the cancers. Autologous peripheral blood stem cell transplantation has been demonstrated to be the most effective treatment method for blood malignancies in HIV-infected patients, to date. In combination with chemotherapy, autologous stem cell transplantation is a highly effective protocol to achieve full remission. Further investigations need to be conducted in order to demonstrate if stem cell transplantation can help reduce the latent viral load in immune cells while simultaneously eliminating cancerous cells. Currently, research shows the viral load is neither increased nor decreased due to autologous peripheral stem cell transplantation.

Keywords

HIV, AIDS, Stem cells, Lymphoma.

Introduction

Due to the ravaging effects of HIV infected individuals are at greater risk compared to the average population at developing secondary illnesses, in particular, opportunistic infections such as herpes simplex, herpes zoster, pneumonia, and cryptococcosis as well as cancers like Kaposi sarcoma, cervical cancer, and lymphomas [1]. Among these illnesses, lymphoma is the leading cause of cancer-related death in the HIV population [2]. The major types of lymphoma seen clinically in HIV patients are non-Hodgkin lymphoma, Diffuse Large B cell lymphoma (DLBCL), Burkitt lymphoma, and Hodgkin lymphoma [2]. Each type of lymphoma is treated with various drug regimens that have proved to be successful; however, no specific drug treatment regimen stands out as better than the rest.

DLBCL drug treatments were evaluated in a study completed in England between 2003 and 2011 [3]. During this time period, HIV patients were given rituximab in addition to cyclophosphamide, doxorubicin, vincristine, and prednisone, also known as the

R-CHOP regimen [3]. The study showed that there was a 78% survival rate five years after treatment. In the United States, a similar study was completed using a drug regimen that included: etoposide, prednisone, vincristine, and doxorubicin (EPOCH) or rituximab in addition to EPOCH [4]. The survival rates were similar, 73%, but neither therapy stood out as the most viable and successful option [4].

Non-Hodgkin lymphoma patients suffer a similar fate. The risk of developing non-Hodgkin lymphoma increases by 11-fold in individuals infected with HIV [5]. Individuals who suffer from HIV have moderate to severe immunosuppression compared to healthy individuals [5]. This puts HIV-infected individuals at higher risk for infection because they do not have a stable and healthy immune system to fight cellular irregularities.

Originally, hematopoietic autologous stem cell transplantation (ASCT) was introduced as a secondary form of treatment following chemotherapy. The stem cells were originally graphed from bone marrow [6]. Now, it is more common to see peripheral blood stem cells as the primary source of transplant cells [6]. Combined with new reduced intensity conditioning regimens, autologous

peripheral blood stem cell transplantation has reduced procedural transplant mortality rates [6]. It has further been shown that the HIV virus does not infect stem cells [8]. As a result, this form of treatment has now been implemented as the gold standard for transplant treatment.

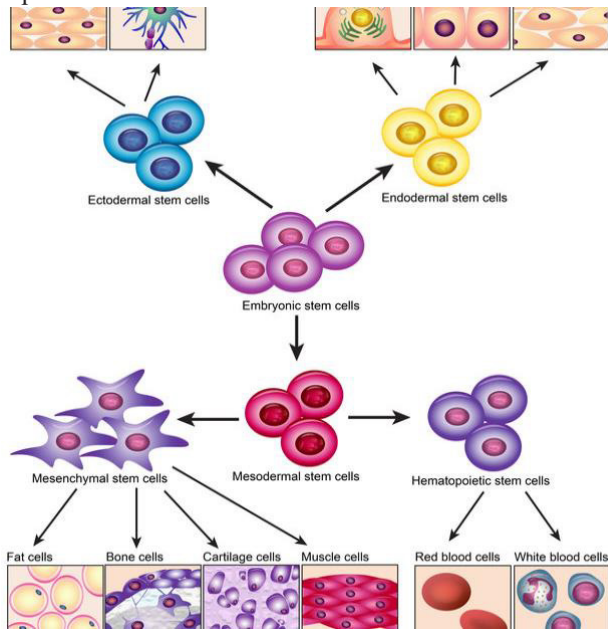


Figure 1: Stem cells go through various stages of growth. They begin as embryonic stem cells and then develop into one of three types of stem cells. The stem cells we are concerned with are hematopoietic stem cells which arise from mesodermal stem cells [7].

Initially, there were concerns using ASCT as an additional form of treatment for HIV-related blood cancers. The first major concern was drug toxicity [2]. It was of concern that individuals would suffer negative health outcomes because their treatment was a combination of chemotherapy drugs, continuous antiretroviral treatment (cART) drugs, as well as any associated pre-transplantation medications. These fears have proven false. Time and time again studies have shown that autologous transplant has been a viable option for treatment with no mortalities [2,9-11]. There is no significant difference between continued cART and interrupted cART during transplantation and it has been shown that autologous transplantation has a clinical efficacy with low risk of infection or toxicity to the patient [10,11].

Because it has been proven that ASCT is safe in combination with chemotherapy regimens and cART, the principle investigation is whether or not stem cell transplantation provides an unequivocal, better form of treatment and even possibly a cure for HIV-related blood cancers compared to chemotherapy treatment on its own.

General Lymphoma

ASCT is a viable, safe, and effective form of cancer therapy treatment for patients who are infected with HIV. In one study, relapsed HIV-associated lymphoma was treated with dexamethasone, cytarabine and cisplatin platinum-based treatment along with ASCT [12]. CD4 lymphocytes did not significantly increase 1, 6 and 12

months after transplantation; however, there was a significant rise in the CD4 lymphocytes three- and five-years' post-transplantation [12]. Despite the effective cancer treatment, the HIV status of the study participants prior to transplantation remained unchanged [12]. Stable plasma viremia loads in patients post-ASCT has been observed in many other studies as well [14-16]. It is believed that transplantation only affects the cancer; while the cART or highly active antiretroviral therapy (HAART) continues to suppress the latent HIV in immune cells [14-17].

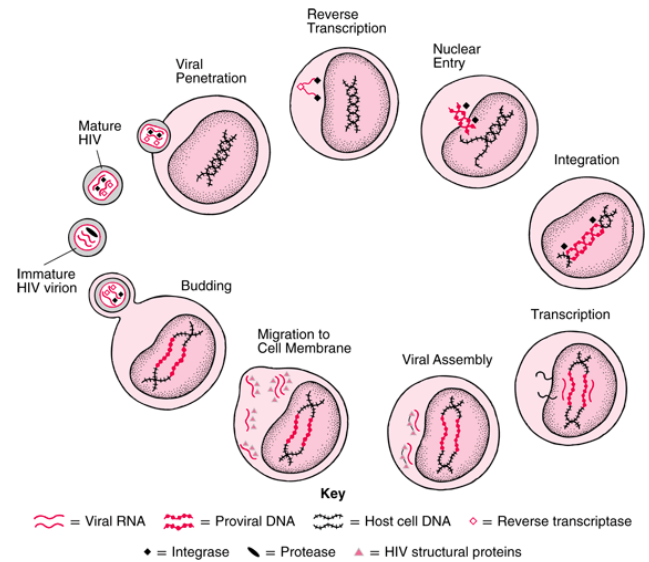


Figure 2: The life cycle of the HIV-1 virus is detailed above. When the cells are in their latent state, the virus has integrated into the genome; however, it is not actively replicating [13].

One possible explanation for the observation of stable viremia loads post-transplantation is that the stem cells are differentiating into T-cells; however, the new T cells don't kill the infected, circulating T cells persisting in the blood. Cells that are circulating in the blood stream with a latent virus within their genome don't present as mutant. The chemotherapy destroys as much of the cancer as possible and then the transplantation stimulates replacement of lost cells. However, neither treatment is aimed at targeting viral loads within immune cells. This is further shown by one study concluding that after ASCT, ten out of ten patients still have HIV DNA detectable in their blood and the plasma viremia was detectable in nine out of ten patients [15].

The best type of chemotherapy treatment or pre-transplantation regimen tends to depend on the cancer. For DLBCL, initially six rounds of R-CHOP or R-EPOCH is the best standardized protocol supported by the literature [18]. However, for Burkitt lymphoma, the best initial chemotherapy regimen is GMALL B-ALL/NHL protocol [18]. In both cases, if the patients are sensitive to relapse then they should receive their standard chemotherapy regimens and then receive ASCT [18]. Regardless of treatment or transplant, it is very important that, if cART is continued throughout the course of treatment, drug interactions are being observed constantly to ensure the health of the patient [18].

If an initial treatment of chemotherapy without transplant fails, a second round of chemotherapy may be warranted. One study showed treatment of relapsed disease has a better response to a second round of chemotherapy than refractory disease [19]. It is important to also use ASCT to combat the cancer because, in all cases, ASCT provides the patient with a significantly longer overall survival rate than without transplant [19]. Interestingly, one study showed that there is no difference in one-year overall survival rates between complete and partial responses to ASCT [19]. It is unclear why this is the case; however, looking at it from a patient's perspective, it is insignificant because the survival rate is still increased.

Non-Hodgkin Lymphoma

Non-Hodgkin Lymphoma (NHL) is one of the many types of lymphomas that has the potential to develop in HIV-infected patients. ASCT, cART and high-dose chemotherapy in combination has led to longer survival of NHL patients with HIV compared to any other treatment combinations [10]. Individually, cART helps to maintain low or barely detectable plasma viral loads. This treatment keeps the viral infection at bay so the high dose chemotherapy can kill cancerous cells. Once the cancer is in remission, ASCT allows the body to regenerate and develop healthy blood cells to replace the ones it lost to the cancer.

A match-study was conducted to evaluate the long-term effects of ASCT. ASCT long term effects had not been previously studied because, originally, ASCT was thought to be too dangerous a procedure for HIV+ patients. Opportunistic infection was found to be slightly higher in HIV+ participants compared to their HIV-counterparts [20]. However, the infections did not result in death and had no effect on survival rates [20]. Infections may have arisen as a result of the transplant or because HIV+ participants are immunocompromised compared with HIV- at the beginning of treatment. Due to this compromised state, opportunistic infection may have been unrelated to the treatment. Overall, it was discovered that ASCT was effective and the status of HIV did not affect long-term transplant results [20].

The transplantation is being administered in these patients as a form of cancer treatment. The goal of the transplant is to eliminate the cancer, not the HIV itself. As mentioned, stem cell transplantation has not been shown to be an eradicable treatment for HIV. cART allows HIV+ individuals to lead a high functioning life without major complications.

A pooled analysis of 1546 patients showed similar results. It was shown that rituximab significantly improved outcomes in HIV-positive CD20+ lymphoma patient outcomes [12]. In a third study, rituximab was shown to be the key to good B cell recovery after transplantation with no significant difference in B cell functionality [10]. T cell recovery remained good as well because the thymus remained competent throughout the transplantation [10]. CD4 cells slowly recovered and then significantly improved between 12 and 24 months after transplantation for HIV positive and negative patients compared to healthy control patients [10].

Along with the use of cART, HAART has greatly improved the prognosis of those with NHL [21]. Combined with more effective infusional regimens, rituximab, and high dose chemotherapy followed by ASCT, this has become the standard of care [21]. Hematopoietic autologous plasma stem cell transplantation on its own only has long term survival rates of only 10% to 50% [22].

Diffuse Large B Cell Lymphoma

Research has showed promise in successfully achieving remission of DLBCL with infusional chemotherapy and ASCT. Currently, the best chemotherapy regimen discovered to treat DLBCL is with the drug rituximab [23]. Initially, there was a lot of controversy over using rituximab as a chemotherapy drug because it was thought to potentially be associated with increased patient infection [24]. An increased risk of infection was exacerbated by low CD4 cell counts in HIV patients [24]. Despite these risks, rituximab improves patient response and possibly overall survival against cancer. Therefore, the benefits of using the drug far outweigh the risks. It was later shown in further investigations of rituximab, that it is a safe, low risk, and highly effective drug [25].

A case study was done on a 62-year-old male diagnosed with advanced lymphoma. Because of advanced staging, the male had a low prognosis of survival and was not expected to live long after diagnosis [26]. The patient received two rounds of CHOP followed by four rounds of CHOP with rituximab [26]. HIV was diagnosed at the same time as the cancer and the patient was immediately started on HAART at the same time as the chemotherapy treatments began [26]. Once the chemotherapy was completed, the patient moved onto the next step in the treatment protocol. The patient received a pre-transplant treatment of ranimustine, etoposide, cytarabine, melphalan (MEAM) followed by ASCT [26,27]. Despite his poor prognosis, the chemotherapy transplant combination put the man into complete remission that was maintained 24 months after transplantation [26].

This case study further proves the power that ASCT and rituximab have at curing HIV+ patients of their disease-related malignancies. As seen in the case study, rituximab did not cause the patient to suffer from severe infection as previously thought. The patient was able to go into complete remission from his cancer.

Burkitt Lymphoma

Burkitt lymphoma is another deadly killer of HIV+ patients. It is currently the second most common AIDS-related lymphoma developed by people of the HIV population [29]. However, after many years of research there is an effective form of treatment against Burkitt lymphoma in HIV+ kids and adults alike. The best way to treat Burkitt lymphoma is with HAART during or immediately after receiving chemotherapy [25]. It is important to note that it is essential to keep a close watch on the interaction between chemotherapy drugs and HAART in an event of toxicity. Despite this slight risk, chemotherapy paired with ASCT treatment is effective at achieving disease free survival in 50% to 80% of people with relapsed or refractory disease [25].

Similar to DLBCL, there was previous controversy with the use of one of the chemotherapy drugs in the regimen, rituximab. Rituximab was rumored to increase death rates as a result of infectious disease; however, this is not confirmed [24]. There are many conflicting reports that show it increases the risk of infectious disease in some patients but not in others [24]. However, what has been consistently shown is that the drug is been proven to be associated with improved health outcomes [25]. The positive benefits of using rituximab far outweighs the risks; therefore, it is included as an important component in the high dose chemotherapy stage of treatment for Burkitt lymphoma.

A case study looked at treatment of a 13-year-old with refractory Burkitt lymphoma [30]. The child first received high dose chemotherapy with rituximab followed by ASCT [30]. The child went into full remission and this remission was successfully maintained 26 months following transplantation [30]. This case study highlights some major trends seen with Burkitt Lymphoma treatment plans. First, the chemotherapy regimen with rituximab followed by ASCT was able to achieve full remission. This remission was maintained for more than two years after transplant and it worked in a child.

This evidence further supports the claim that rituximab is a powerful chemotherapy drug that is strongly associated with positive health outcomes. It also further proves that ASCT should be the gold standard form of treatment for HIV-related malignancies like lymphoma. Time and time again it has proven to be effective, safe, and provide patients with the best possible chance of survival.

Hodgkin's Lymphoma

HAART treatment has been very successful at minimizing the immunocompromised component in HIV patients. Because it helps to maintain low viral loads, patients currently receiving HAART have immune systems that are able to handle infection better because the virus is not continually destroying white blood cells compared to the past. A better immune system in turn leads to a lower risk at developing blood malignancies and primitive lymphoma of the central nervous system has decline drastically [31]. However, as rates of blood cancers decrease, the rate of developing a Hodgkin's lymphoma (HL) tumor is increasing [31]. Although the immune system is better at combating malignancies in the blood, it has not been seen to reduce non-AIDS defining tumor formation [31].

HL is one of the most common tumor types that affect HIV-infected patients [32]. Chemotherapy has proved to be an effective form of treatment for patients with HL. Chemotherapy does not have to be paired with other forms of treatment to be effective at improving overall survival [32]. However, the goal is not to only improve overall survival but to achieve complete remission. Chemotherapy alone has not been effective at achieving this. If complete remission is the goal, the pathway to achieving that requires a combination of medical approaches.

Currently, there is no optimal therapy outlined in the literature

for HL because of rising incidence rates [25]. Research has been primarily focused on reducing the viral load in HIV afflicted individuals and achieving an immune state that allows HIV individuals to be fully functioning. The rising incidence rates have not been in focus until recently. Despite the lack of standard treatment protocols, a case study done on a 44-year-old patient showed that high dose chemotherapy followed by ASCT was an effective way to achieve complete remission [33]. The patient was diagnosed with relapse, stage four HL. After receiving the aforementioned treatments, complete remission was achieved and maintained 59 months after transplantation [33].

This case study shows that the general protocol of high dose chemotherapy paired with ASCT can be an effective treatment plan options for patients with early stages as well as late stages of lymphoma. Although it is typically more successful when the cancer is in the earlier stages, it is clear that it is still an optional and effective treatment protocol [34]. Further investigations into the best drug regimen to use for the high dose chemotherapy will be the next step in developing a standardized, optimal treatment protocol for patients suffering from the ever-increasing incidence of HL tumors.

Further Investigations

The marked success of a cure as a result of allogenic stem cell transplantation is exemplified by the Berlin patient and recently the London patient. Both patients received stem cell transplantation with the primary goal of eradicating their cancers. However, both patients also experienced an eradication of their HIV as well. Both patients received transplantations with stem cells containing the 32 base pair deletion of the CCR5 Δ 32/ Δ 32 [35]. The deletion of this allele is extremely important because HIV-1 utilizes this chemokine receptor to enter and infect cells. Without this receptor, the virus cannot cause infection [35]. Both the Berlin and London patients also underwent similar graft versus host disease (GvHD) drug regimens prior to transplantation. The Berlin patient utilized the standard CsA + MMF regimen while the London patient used the CsA + MTX regimen [36].

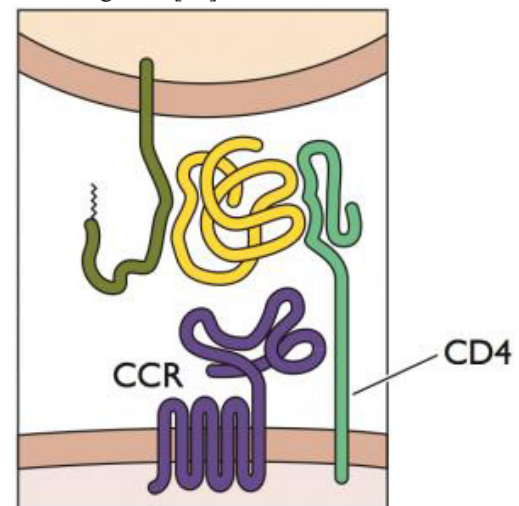


Figure 4: Depicted above is the receptor that HIV-1 exploits to enter into the cell. Both the CCR and CD4 components are required for viral entry.

When the cell does not code for the CCR region, the virus is unable to infect the cell [37].

Upon transplantation, the London patient received LACE conditioning and then an infusion of 3.6×10^6 CD34+ cells/kg [38]. The Berlin patient received 2.3×10^6 CD34+ cells/kg and then underwent a second transplantation from the same donor 391 days later of 2.1×10^6 cells/kg [35]. In both cases, both patients suffered mild GvHD despite their transplant regimens, but it is believed this played a role in eradicating the virus [39].

In comparison to autologous stem cell transplantation, allogeneic stem cell transplantation has been shown to not only eradicate cancer but also HIV in its patients. However, this is not currently a viable option for treatment of HIV+ patients on a large scale. It currently is under further research to better understand the mechanisms behind the viral eradication as well as understanding how to replicate the treatment on a safe, large-scale application.

In an effort to achieve this, researchers in China have recently investigated the safety and efficacy of utilizing clustered regularly interspaced short palindromic repeats (CRISPR) as a way to induce the CCR5 mutation into the human genome in conjunction with transplantation of stem cells [40]. The goal of the CCR5-ablated hematopoietic stem and progenitor cell transplantation was to eradicate HIV in a man suffering from HIV-1 infection along with Acute Lymphocytic Leukemia. This goal was not achieved [40]. Only a small portion of the CD4+ cells, 5%, showed phenotypic characteristics of the CCR5 disruption [40].

However, this research is significant because after transplantation, full remission of the cancer was achieved and the safety of utilizing CRISPR was exemplified [40]. Up until this study, it was unsure if CRISPR was a safe way to edit the genome and if it would induce other unfavorable outcomes as a result of the gene editing. This research showed that donor cells could persist in the patient for more than 19 months without causing adverse reactions [40]. Further investigations into the utilization of CRISPR as a technology induce the CCR5 mutation desirable for achieving immunity to HIV need to be made.

In addition to investigating viable allogeneic transplantation, investigations into reducing the peripheral viral reservoir need to be completed for autologous stem cell transplantation. High-dose chemotherapy and autologous transplant have shown unpredictable influences on viral reservoirs. In a study, one treatment group showed HIV-DNA levels plateau between 6 and 12 months of follow up [41]. Some patients even saw higher peripheral DNA loads after transplant and interruption of cART post-transplant [41]. No association was found between baseline and post-transplant viral loads. However, one sub-group of patients were found to have an association between peripheral blood HIV reservoir size and autologous stem cell transplantation. It could potentially be influenced by the mobile phase and post-transplant continuous cART warranting further works be conducted [41].

Conclusion

There are many positives to using ASCT in combination with chemotherapy as a form of treatment for HIV-related lymphomas. Despite all of the benefits; however, there are certain characteristics of a patient's illness that need to be considered prior to transplantation. Although the majority of literature supports ASCT as being a safe and low-risk treatment option now that reduced intensity conditioning treatments are available for HIV patients, aspects of a patient's illness such as stage of lymphoma, DNA levels, and the presence of the Epstein-Barr virus (EBV) can produce variable and even undesirable outcomes [42-44].

Initially, there were questions about whether the status of HIV would be a risk factor in the mobilization of the stem cells used in the transplantation. A comparison study was performed between HIV+ and HIV- patients [42]. Both groups of patients were given ASCT with peripheral blood stem cells. It was discovered that the only factor affecting the mobilization of the stem cells was the status of the lymphoma at the time of transplant [42]. Lymphomas at a more advanced stage were correlated with lower mobilization success into remission. If the transplant was performed before the lymphoma had progressed into a late stage, it had a much higher success of mobilization into remission [42].

Along with the stage of lymphoma, the amount of HIV DNA may be correlated to successful transplantation. In HIV patients, at baseline the amount of CD4 white blood cell counts are independent of HIV DNA levels. HIV DNA levels are instead correlated with HIV RNA levels [43]. Typically, these levels are controlled and kept at low levels by cART or HAART treatment. When HIV+ patients take these medications daily and continually throughout treatment, transplantations are more successful. High DNA levels can potentially be a predictor for overall survival after ASCT [43]. It was shown that patients with high DNA levels at baseline prior to treatment had a near significant increased risk of death compared to low HIV DNA levels [43].

HIV DNA levels are not the only factor that may be detrimental to the success of ASCT. EBV can also have negative effects on transplantation outcomes. Patients who undergo high dose chemotherapy and autologous peripheral blood stem cell transplantation are more chemo-sensitive and have a significantly higher risk of mortality if the EBV is present [43]. In a study conducted with 22 HIV+/EBV+ patients, five of the patients died within six months of transplantation completion [44].

When considering a patient for ASCT transplant as a treatment option following high dose chemotherapy, it is important to keep many factors in mind to ensure success. The stage of lymphoma as well as HIV DNA loads and the presence of EBV should all be factors investigated prior to treatment. If there are high levels of HIV DNA or EBV, a different treatment option other than ASCT should be considered. If ASCT is decided as the best treatment option, cART or HAART should be continued when the treatment plan is being carried out; however, drug interactions and toxicity should be monitored closely. ASCT has shown to be an effective

and safe treatment option, curing many patients of HIV-related lymphomas. Its success is ensured with the proper planning and investigation for each individual patient.

Acknowledgments

I would like to thank Dr. Vincent Gallicchio for his guidance and expertise throughout the completion of this paper.

References

1. <https://www.hiv.va.gov/patient/diagnosis/OI-common-illnesses.asp>
2. Hunter, Natasha B, Samantha Vogt, et al. Treatment of HIV-Associated Lymphomas: The Latest Approaches for Optimizing Outcomes. *Oncology (Williston Park)*. 2017; 31: 872-877.
3. Coutinho R, Pria AD, Gandhi S, et al. HIV status does not impair the outcome of patients diagnosed with diffuse large B-cell lymphoma treated with R-CHOP in the cART era. *AIDS*. 2014; 28: 689-697.
4. Sparano JA, Lee JY, Kaplan LD, et al. Rituximab plus concurrent in fusional EPOCH chemotherapy is highly effective in HIV-associated B-cell non-Hodgkin lymphoma. *Blood*. 2010; 115: 3008-3016.
5. Gibson TM, Morton LM, Shiels MS, et al. Risk of Non-Hodgkin Lymphoma Subtypes in HIV-Infected People during the HAART Era: A Population-Based Study. *Aids*. 2014; 28: 2313-2318.
6. Krishnan, Amrita. Stem Cell Transplantation in HIV-Infected Patients. *Current Opinion in HIV and AIDS*. 2009; 4: 11-15.
7. Luk, Franka, Eggenhofer, et al. Core concept: The Use of Stem Cells for Treatment of Diseases. *Frontiers for young minds*. 2017.
8. Weichold F, Zella D, Barabitskaja O, et al. Neither Human Immunodeficiency Virus (HIV-1) nor (HIV-2) infects most primitive human hematopoietic stem cells as assessed in long term bone marrow cultures. *Blood*. 1998; 91: 907-915.
9. Mulanovich, Victor, Parth Desai, et al. Allogeneic Stem Cell Transplantation for HIV-Positive Patients with Hematologic Malignancies. *Aids*. 2016; 30: 2653-2657.
10. Diego Bertoli, Alessandro Re, Marco Chiarini, et al. B- and T-Lymphocyte Number and Function in HIV. *Scientific Reports*. 2016; 6: 37995.
11. Zanussi Stefania, Bortolin MT, Pratesi C, et al. Autograft HIV-DNA Load Predicts HIV-1 Peripheral Reservoir After Stem Cell Transplantation for AIDS-Related Lymphoma Patients. *AIDS Research and Human Retroviruses*. 2015; 31: 150-159.
12. Barta Stefan K, Xue X, Wang D, et al. Treatment Factors Affecting Outcomes in HIV-Associated Non-Hodgkin Lymphomas: A Pooled Analysis of 1546 Patients. *Blood*. 2013; 122: 3251-3262.
13. https://www.msmanuals.com/en-kr/professional/multimedia/figure/inf_hiv_life_cycle_pe
14. Ramaswami R, Pria AD, Parker K, et al. Outcomes of Autologous Stem Cell Transplantation (ASCT) in Patients with Relapsed/Refractory HIV-Associated Lymphoma. *Bone Marrow Transplant*. 2016; 51: 1609-1611.
15. Cillo AR, Krishnan A, Mitsuyasu RT, et al. Plasma Viremia and Cellular HIV-1 DNA Persist Despite Autologous Hematopoietic Stem Cell Transplantation for HIV-Related Lymphoma. *JAIDS Journal of Acquired Immune Deficiency Syndromes*. 2013; 63: 438-441.
16. Thera Lee S. Persistence of Virus Reservoirs in ART-Treated SHIV-Infected Rhesus Macaques After Autologous Hematopoietic Stem Cell Transplant. *PLoS Pathogens*. 2014; 10: e1004406.
17. Anthony R Cillo, Supriya Krishnan, Deborah K McMahon, et al. Impact of Chemotherapy for HIV-1 Related Lymphoma on Residual Viremia and Cellular HIV-1 DNA in Patients on Suppressive Antiretroviral Therapy. *PloS One*. 2014; 9: e92118.
18. Hentrich Marcus, Hoffmann C, Mosthaf F, et al. Therapy of HIV-Associated Lymphoma-Recommendations of the Oncology Working Group of the German Study Group of Physicians in Private Practice Treating HIV-Infected Patients (DAGNÄ), in Cooperation with the German AIDS Society (DAIG). *Annals of Hematology*. 2014; 93: 913-921.
19. Ramaswami R, Pria AD, Parker K, et al. Outcomes of Autologous Stem Cell Transplantation (ASCT) in Patients with Relapsed/Refractory HIV-Associated Lymphoma. 2016; 51: 1609-1611.
20. Krishnan A, Palmer JM, Zaia JA, et al. HIV Status does Not Affect the Outcome of Autologous Stem Cell Transplantation (ASCT) for Non-Hodgkin Lymphoma (NHL). *Biology of Blood and Marrow Transplantation*. 2010; 16: 1302-1308.
21. Mounier Nicolas, Michele Spina, Christian Gisselbrecht. Modern Management of Non-Hodgkin Lymphoma in HIV-Infected Patients. *British Journal of Haematology*. 2007; 136: 685-698.
22. Steingass, Sharon K. Hematopoietic Cell Transplantation in Non-Hodgkin's Lymphoma. *Seminars in Oncology Nursing*. 2006; 22: 107-116.
23. Gucalp Ayca, Ariela Noy. Spectrum of HIV Lymphoma 2009. *Current Opinion in Hematology*. 2010; 17: 362-367.
24. Dunleavy, Kieron, Wyndham H Wilson. How I treat HIV-associated lymphoma. *Blood*. 2012; 119: 3245-3255.
25. Levine, Alexandra M. Management of AIDS-Related Lymphoma. *Current Opinion in Oncology*. 2008; 20: 522-528.
26. Nagai Y, Mori M, Inoue D, et al. Successful Treatment with Autologous Peripheral Blood Stem Cell Transplantation for Acquired Immunodeficiency Syndrome (AIDS)-Related Malignant Lymphoma. *Rinsho Ketsueki*. 2009; 50: 1641-1646.
27. Kawabata KC, Hagiwara S, Takenouchi A, et al. Autologous Stem Cell Transplantation using MEAM Regimen for Relapsed AIDS-Related Lymphoma Patients Who Received Highly Active Anti-Retroviral Therapy: A Report of Three Cases. *Internal Medicine*. 2009; 48: 111-114.
28. <https://www.rituxanhycela.com/patient/dlbcl/what-is-dlbcl/signs-and-symptoms.html>
29. Werutsky G, de Carvalho GP, da Silva VD, et al. AIDS-Related Sinonasal Burkitt Lymphoma Successfully Treated with Intensive Chemotherapy Regimen and High Active

- Antiretroviral Therapy. *Hematology/Oncology and Stem Cell Therapy*. 2011; 4: 41-44.
30. Fluri S, Ammann R, Lüthy AR, et al. High-Dose Therapy and Autologous Stem Cell Transplantation for Children with HIV-Associated Non-Hodgkin Lymphoma. *Pediatric Blood & Cancer*. 2007; 49: 984-987.
 31. Malfitano A, Barbaro G, Perretti A, et al. Human Immunodeficiency Virus-Associated Malignancies: A Therapeutic Update. *Current HIV Research*. 2012; 10: 123-132.
 32. Martis Nihal, Nicolas Mounier. Hodgkin Lymphoma in Patients with HIV Infection: A Review. *Current Hematologic Malignancy Reports*. 2012; 7: 228-234.
 33. Gabriel I, Apperley J, Bower M, et al. A Long-Term Durable Remission with High-Dose Therapy and Autologous Stem Cell Transplant for Stage IVB HIV-Associated Hodgkins Disease. *AIDS*. 2008; 22: 539-540.
 34. Krishnan Amrita, Stephen J Forman. Hematopoietic Stem Cell Transplantation for AIDS-Related Malignancies. *Current Opinion in Oncology*. 2010; 22: 456-460.
 35. Hutter G, Daniel Nowak, Maximilian Mossner, et al. Long-term control of HIV by CCR5 Delta32/Delta32 stem-cell transplantation. *N Engl J Med*. 2009; 360: 692-698.
 36. Hamilton BK, Bolwell B, Kalaycio M, et al. Long-term follow-up of a prospective randomized trial comparing CYA and MTX with CYA and mycophenolate mofetil for GVHD prophylaxis in myeloablative sibling donor hematopoietic cell transplantation. *Bone Marrow Transplant*. 2013; 48: 1578-1580.
 37. www.virology.ws/2019/03/13/the-london-patient/
 38. Ravindra K Gupta, Sultan Abdul-Jawad, Laura E McCoy, et al. HIV-1 Remission Following CCR5 Δ 32/ Δ 32 Haematopoietic Stem-Cell Transplantation. *Nature*. 2019; 568: 244-248.
 39. Salgado M, Kwon M, Gálvez C, et al. Mechanisms That Contribute to a Profound Reduction of the HIV-1 Reservoir After Allogeneic Stem Cell Transplant. *Ann Intern Med*. 2018; 169: 674-683.
 40. Xu Lei, Jun Wang, Yulin Liu, et al. CRISPR-Edited Stem Cells in a Patient with HIV and Acute Lymphocytic Leukemia. *New England Journal of Medicine*. 2019; 381: 1240-1247.
 41. Zanussi S, Bortolin MT, Pratesi C, et al. Autograft HIV-DNA load predicts HIV-1 peripheral reservoir after stem cell transplantation for AIDS-related lymphoma patients. *AIDS research and human retroviruses*. 2015; 31: 150-159.
 42. Sagüés M, Sancho JM, Serrano D, et al. Comparison of Two Initial Mobilizing Strategies of Peripheral Blood Stem Cells for Autologous Transplantation in Patients with Lymphoma and Human Immunodeficiency Virus Infection. *Medicina Clinica*. 2012; 139: 192-196.
 43. Bortolin MT, Zanussi S, Talamini R, et al. Predictive Value of HIV Type 1 DNA Levels on overall Survival in HIV-Related Lymphoma Patients Treated with High-Dose Chemotherapy (HDC) Plus Autologous Stem Cell Transplantation (ASCT). *AIDS Research and Human Retroviruses*. 2010; 26: 245-251.
 44. Pratesi C, Zanussi S, Tedeschi R, et al. Γ -Herpesvirus Load as Surrogate Marker of Early Death in HIV-1 Lymphoma Patients Submitted to High Dose Chemotherapy and Autologous Peripheral Blood Stem Cell Transplantation. *PloS One*. 2015; 10: e0116887.