

The Retino-Hypothalamic Ultrastructural Changes in Traumatic Optic Neuropathy

Moyseyenko N, MD*

Department of Otolaryngology and Ophthalmology, Ivano-Frankivsk National Medical University, Ukraine.

*Correspondence:

Moyseyenko Nataliya, MD, Department of Otolaryngology and Ophthalmology, Ivano-Frankivsk National Medical University, Ukraine, 118 Halitska str. 13., Ivano-Frankivsk, 76008, Ukraine, Orcid.org/0000-0001-5488-1390.

Received: 20 June 2021; Accepted: 01 August 2021

Citation: Moyseyenko N. The Retino-Hypothalamic Ultrastructural Changes in Traumatic Optic Neuropathy. J Med - Clin Res & Rev. 2021; 5(8): 1-7.

ABSTRACT

Aim: To study the retino-hypothalamic ultrastructural changes in traumatic optic neuropathy's pathogenesis and treatment.

Methods: Four groups of mature rabbits were included in this experiment, 30 in each group, 120 in total. The traumatic crush to the optic nerves was reproduced by surgical clips to 90 mature rabbits. The first group (I) included intact/control animals, the second (II) included animals with traumatic optic neuropathy and two other traumatized groups (III and IV) who were given two different doses of treatment. The animals in group III were given infusions of Methylprednisolone 30mg/kg/day for three days. The group IV animals received infusion of 15mg/kg/day of Methylprednisolone for 3 days in combination with phosphine electric stimulation (PES), starting from the third until the 13th day of the experiment. The electrical pulse which was used on the affected side of the animal was 800 mA and 300 mA on the opposite side. The morphological analysis of the retina and suprachiasmatic nucleus of the hypothalamus of all the four groups of animals included electron microscopy of the semi-thin and ultrathin sections. This analysis was performed a month following the initial injury while the animals were removed from the experiment. The levels of cortisol and adrenocorticotropic hormone (ACTH) in the blood of all experimental animals was tested up to one month following the injury to the optic nerves.

Results: We found that trauma to the orbital part of the optic nerve causes collocative necrosis of ganglion cells and swelling of the nerve fiber layer of the ipsilateral retina. In addition, such traumatic damage causes structural changes in the suprachiasmatic nucleus of the hypothalamus. Combined treatment of methylprednisolone with phosphine electro stimulation in traumatized rabbits reduced the thickness of the retina, reduced the cytokaryometric indices and the regeneration processes of bipolar and ganglion cells of the retina. Histopathologically we found an increased number of neurosecretory granules in the suprachiasmatic nucleus of the hypothalamus. ACTH levels in the blood of the group III rabbits were found to be lower, while the cortisol levels higher, and these hormone levels in the IV group rabbits were quite similar to those of the group which was not treated.

Conclusion: The combined treatment of traumatic optic neuropathy in rabbits with phosphine electrostimulation and methylprednisolone can be considered a useful treatment, having a beneficial neuroprotective effect.

Keywords

traumatic optic neuropathy, retina, neuroprotective therapy, suprachiasmatic nucleus of the hypothalamus, neurosecretory granules, phosphine electric stimulation.

Introduction

The activation of the hypothalamic suprachiasmatic nucleus by light was first reported by Bremer [13]. The peptides of the supraoptic and paraventricular nuclei activate the synthesis of nerve tissue growth factor [15,16]. The mutation of this factor promotes growth, differentiation of vegetative system's elements and changes its neurosecretory properties [11]. It is also known that the suprachiasmatic nucleus regulates the secretion of the light dependent corticosteroids [12,14].

The neural secretion of the hypothalamic nucleus is also activated by phosphine electric stimulation (PES). PES influence on cerebral vessels' tone is independent of neural secretion synthesis of the magnocellular neurons of the supraoptic hypothalamic nucleus. Stimulation by current of 100 μ A and 300 μ A can cause the redistribution of the contents of different types of neurons in the supraoptic nucleus of the hypothalamus [1,8].

These mechanisms led us to the conclusion that retino-hypothalamic stimulation could be used in traumatic optic neuropathy (TON) to ensure the production of endogenous corticosteroids, which could reduce the dosage of 30 mg/ kg Methylprednisolone, being the standard TON treatment [12]. This could also reduce the toxic effects of the high doses of corticosteroids, while preserving their neuroprotective effect.

The purpose of the research was to study the retino-hypothalamic ultrastructural changes in traumatic optic neuropathy, its pathogenesis and preferred treatment.

Materials and methods

The experimental traumatic optic nerve crush was reproduced in 90 sexually mature rabbits of the chinchilla breed by surgical clips [7], according to the suggestion of the Bioethics Commission and approved by the Ivano-Frankivsk National Medical University in 2016.

The animals were divided in the following groups: intact (I), experimental (II) and 2 groups with different treatments (I and II) having 30 animals in each (120 animals in total). Group III animals received 30 mg/kg methylprednisolone for three days. Group IV received 15 mg/kg methylprednisolone combined with a PES current of 800 mA on the side of the lesion and 300 mA on the opposite side, from the third till the 1th day (Figure 1)

The morphological analysis (electron microscopy of the semithin and ultrathin sections and morphometry) of the retina and suprachiasmatic (supraoptic) nucleus of the hypothalamus in all the above groups after having removed by guillotine, was done one month after the trauma at the electron microscopy laboratory of the Anatomy Department of Ivano-Frankivsk National Medical University.

The maintenance of all the animals up to 1 month after injury and their removal from the experiment, were performed in accordance with the "Requirements of Bioethics of the Helsinki Declaration on the Ethical Regulation of Medical Research".

The analysis of the cortisol and adeno-corticotrophic hormone (ACTH) levels in the serum of the experimental animals of all the groups up to one month after injury was carried out at 9.00 o'clock.

Results

In the retina specimen of the side of the crushed optic nerve in group II, there was a significant thickening of the retina in comparison with the control group (I) from $178,5 \pm 11,47 \mu\text{m}$ to $246,85 \pm 23,69 \mu\text{m}$. Specifically, there was an increase in the thickness of the photosensory layer (PSL) by 70,8%, outer nuclear layer (ONL) by 54,9%, internal nuclear layer (INI) by 40,1%, ganglion cell layer (GCL) by 53%, and nerve fiber layer (NFL) by 35%.

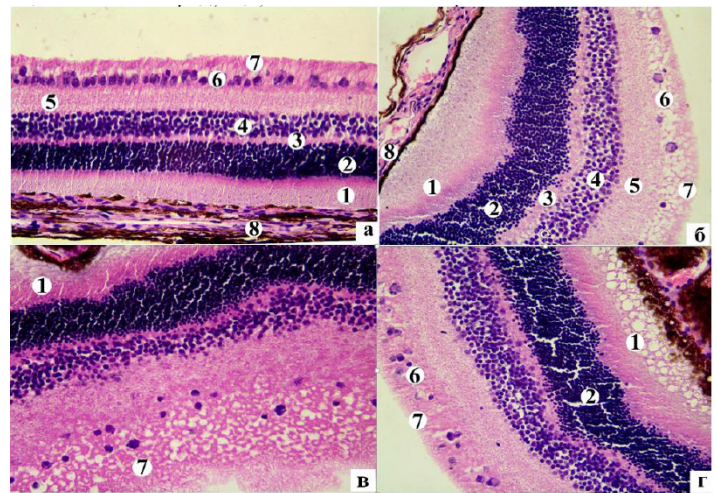


Figure 1: The histostucture of the retina of group I rabbits (a) and its edema on the affected side in group II animals at 14 (b) and 30 (c, d) days after optic nerve fragmentation. Staining with hematoxylin and eosin. Microphotography.: a, b, c) 400.

Notes: b, c - edema of INL (4), ONL (2) and GCL (6); relocation of nuclei from SNF (4) to SSR (3); microcystic degeneration of ganglion neurons (6), thickening and enlighthentment of nerve fibers of NFL (7).

In addition, in the group II animals there was swelling in ONL, INL and GCL (Figure 2 6, B). There was also microcystic degeneration of ganglion cells and pericellular edema in the GCL. A significant decrease in the number of multipolar neurons was observed in the GCL in comparison with the intact group of animals (Figure 2 a). The total area of these neurons had increased while compared with intact animals from $58,81 \pm 9,01 \mu\text{m}^2$ to $71,68 \pm 8,87 \mu\text{m}^2$ ($P < 0,01$), where as the core area did not significantly change and was $37,06 \pm 36,20 \mu\text{m}^2$ (intact group - $36,20 \pm 6,63 \mu\text{m}^2$). This lead to a decrease in the nuclear-cytoplasmic index (NCI) from $1,14 \pm 0,36$ to $1,14 \pm 0,36$ ($P < 0,03$). There was also thickening and enlighthentment of NFL.

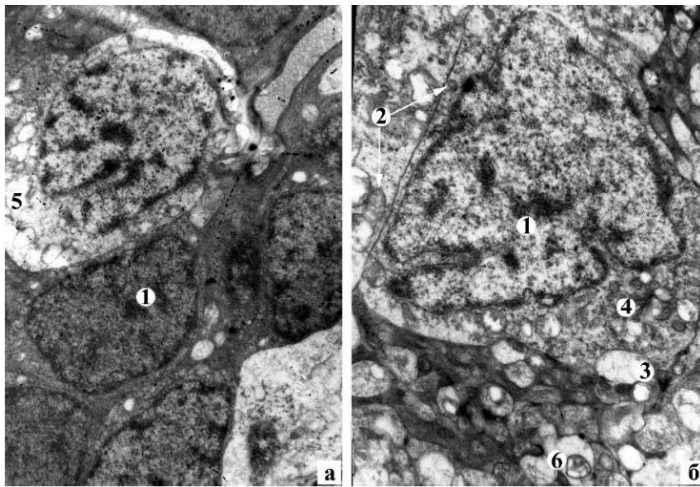


Figure 2: Dystrophic-destructive changes of bipolar (a) and ganglionic neurons on the side of the lesion (b) in rabbits of group II after fragmentation of the optic nerve. Electronic microphotographs: a) 4800, b) 6400.

Notes: 1 - karyopyknosis and intussusception of the nuclear envelope, 2 - mitochondria with disorganized crystals and with destroyed inner membrane, 3 - vacuoles, 4 - tanks, 5 - colic necrosis of the neuron, 6 - enlightenment of the neuron axoplasm in the sharon neuron.

In the *suprachiasmatic nucleus (SN)* of the hypothalamus in the experimental group (II) on the 30th day after injury of the right optic nerve, there were a number of neural cells (NC) with peripheral chromatolysis and enlarged hypochromic nuclei with "shadow cells" appearance (Figure 3). Some NC with small vacuoles on the pericarp of the perikaryon were seen. There was karyopyknosis and some cariolysis in the majority NC. The area of perikaryon SN in comparison with the intact group increased to $276,59 \pm 38,02 \mu\text{m}^2$ ($P < 0,05$), where as the area of the core field of nuclei did not change significantly - $71,93 \pm 15,67 \mu\text{m}^2$ ($P > 0,05$). NCI decreased to $0,35 \pm 0,07$ ($P < 0,01$). This does not indicate NC's functional activation, but destructive changes of swelling of the nuclei and the cells.

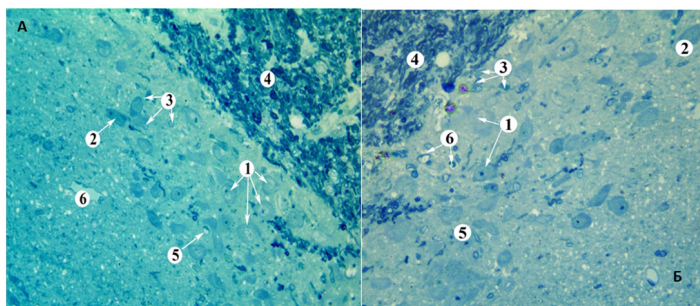


Figure 3: Histostructure of the SN of the rabbit is normal (A) and 30 days after fragmentation of the orbital part of the optic nerve (B). Semi-thin slice, painted methylene blue.

Symbols: A. 1 - normochromic neurons, 2 - hyperchromic, 3 - gliocytes, 4 - visual junction, 5 - capillary, 6 - venule; B. 1 - NC with the phenomena of peripheral chromatolysis, 2 - hyperchromic, 3 - gliocytes, 4 - visual junction, 5 - shadow cells, 6 - capillary.

At the ultrastructural level of *the retina*, neurons with dystrophic and destructive changes in the INL (Figure 4a) were observed. Also, karyopycnosis, invaginations of the nuclear shell, enlightenment and vacuolation of the cytoplasm and single neurons in the state of collective necrosis were seen. In GCL, great part of neurons had cytoplasm with small vacuoles (Figure 4 b). The nuclei acquired a triangular and irregular shape due to significant invasions of the nuclear shell, indicating reactive changes in the cell. The granular endoplasmic reticulum was expanded, some of them destroyed, others shortened, containing attached single ribosomes. A part of the mitochondria in the cells had a normal ultrastructural organization, others were partially disorganized and the rest - had a broken inner membrane. Some capillaries with significant edema of the endothelial cells were seen, which blocked the lumen of the vessels, and were encountered in the NFL. Around these capillaries perivascular edema was seen. In part of the nerve fibers of NFL axonal degeneration was seen, which morphologically manifested itself by electron-transparent axoplasm, decrease in the number of neurofilaments on the background of complete absence of microtubules; disorganization and destruction of mitochondrial crests.

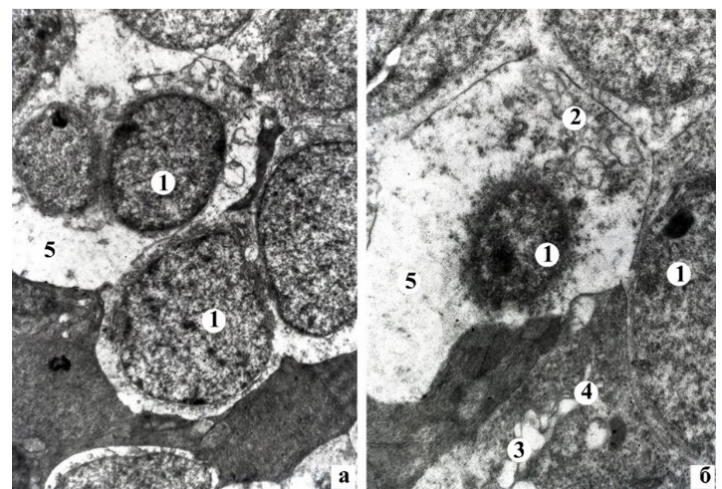


Figure 4: Dystrophic-destructive changes of bipolar (a) and ganglionic neurons (b) of the II group of rabbits on the 30th day after fragmentation of the orbital part of the optic nerve. Electronic microphotographs: a) 4800, b) 8000.

Symbols: 1 - neuron nucleus, 2 - mitochondria, 3 - vacuoles, 4 - expanded granular endoplasmic reticulum tanks, 5 - colic necrosis of the neuron.

In the cytoplasm, an expansion of the granular endoplasmic reticulum, illumination of the mitochondrial matrix and destruction of crystals with subsequent formation of vacuoles were seen in the majority of light NC of *SN's hypothalamus*. In addition, an increase in the number of primary and secondary lysosomes and destruction of the Golgi complex were observed (Figure 5). The nuclei had low optical electron density with minor invasions of the nuclear shell, and there were also isolated light NC with hydropic dystrophy. The volume density of NG in the light neurons was significantly reduced to $2,24 \pm 0,19\%$ ($P < 0,02$) compared to the intact group of animals. The small vacuoles and lysosome were

increased in number and granular endoplasmic reticulum and single NG were found in the neuropil of dark NCs. Their nuclei had one or two nucleoli. The volumetric density of dark NG was significantly reduced to $1,14 \pm 0,04\%$ ($P < 0,02$) compared with intact animals.

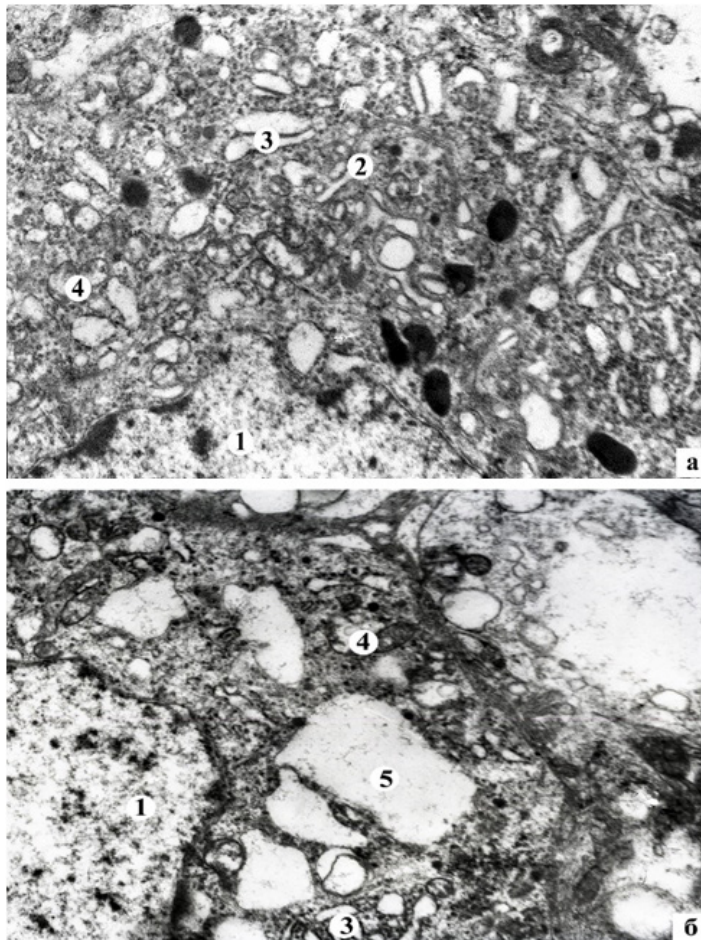


Figure 5: Reactive changes (a) and hydropic dystrophy (b) of rabbit NS neurons for 30 days after fragmentation of the orbital part of the optic nerve.

Symbols: 1 - NC nuclei are of low electron-optical density with slight intussusception of the nuclear envelope, 2 - destruction of structural elements of the Golgi complex, 3 - expansion of HPP tanks, 4 - enlightenment of the mitochondrial matrix and destruction of crystals, 5 - vacuoles.

The treatment of 14 days in the animals of groups III and IV, compared with group II, resulted in a significant decrease in the thickness of the retina. The thickness of the retina in group III was $216,74 \pm 20,14 \mu\text{m}$ and in group IV - $203,82 \pm 18,49 \mu\text{m}$. However, these results were significantly higher in comparison to the intact group of animals. At light microscopy enlargement, reduction of edema in the different layers of the retina and restoration of its histological structure were observed (Figure 6). In the GCL of the retina of the third group of animals, the number of neurons were negligible and they were small in size. In the fourth group,

the ganglionic neurons were similar to the intact retina by size and location (Figure 6). Qualitative data were confirmed by morphometric indices. Thus, in group III, the area of the ganglion cells, their nuclei and NCIs were significantly lower than those of the I and II groups of animals and were respectively $39,42 \pm 6,15 \mu\text{m}^2$, $20,97 \pm 6,38 \mu\text{m}^2$, $1,22 \pm 0,44$. In group IV, the area of the ganglion cells, their nuclei and NCI were smaller than in the second group. They were respectively $60,03 \pm 11,7 \mu\text{m}^2$ ($P < 0,01$), $36,33 \pm 8,69 \mu\text{m}^2$ ($P < 0,01$), $1,70 \pm 0,79$ ($P < 0,05$). Such indices of ganglion cells in the group IV of rabbits are not significantly different from those of the intact animals (in all cases, $P < 0,05$).

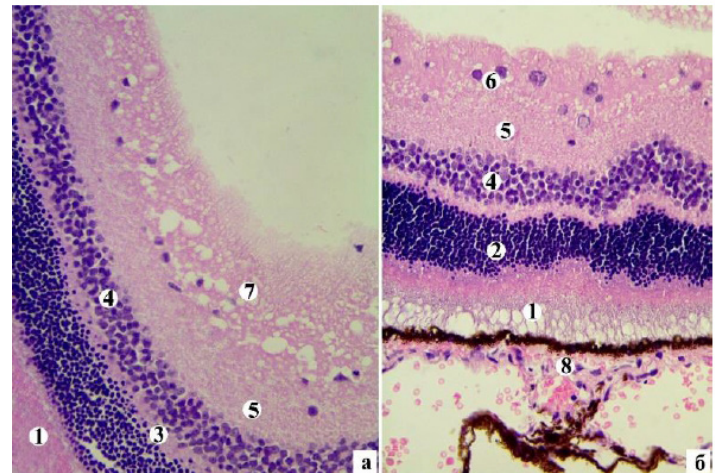


Figure 6: Histostructure of the right retina of group III a (a) and group III (b) of rabbits at 14 days of treatment. Staining with hematoxylin and eosin. Microphotographs: a, b x400.

Notes: 1 - PHL, 2 - ONL, 3 - OPL, 4 - INL, 5 - IPL, 6 - INL, 7 - NFL, 8 - pigment layer of the retina.

In group III and IV rabbits there was a recovery of SN's hypothalamus structure, after receiving treatment during a month. There were central chromatolysis of neurons. In group IV animals most of the neurons had diffusely located tigroid granules (as a sign of regeneration), while the animals of group III had solitary NCs.

In the group III and IV animals the area of perikaryons was significantly decreased to $232,14 \pm 56,81 \mu\text{m}^2$ ($P < 0,04$) and $224,25 \pm 58,26 \mu\text{m}^2$ ($P < 0,05$) compared with the group II, and was not significantly different from the intact group (I) of animals ($P < 0,05$). It obviously indicates the presence of edema. The nuclei of animals in groups III and IV did not significantly change and measured $63,46 \pm 14,38 \mu\text{m}^2$ and $76,51 \pm 16,54 \mu\text{m}^2$ (in all cases, $P < 0,05$) in comparison to the intact animals. The NCI significantly increased to $0,56 \pm 0,23$ ($P < 0,03$) while compared to the measurement in the pathology group and did not differ significantly from that in the intact animals ($P > 0,05$) and in the group IV animals. There was no significant difference from the measurements in the group III and II animals. The NCI of the group III was $0,39 \pm 0,09$ ($P > 0,05$) and was statistically lower than in the intact animals ($P < 0,03$).

After the treatment at the ultrastructural level, traces of regenerative processes were observed *in the retina* (Figure 7). There was enlightenment of the neuroplasia of the individual perikaryons and disorganization of the mitochondria in the neurons of the INL. In the GCL of group III, most of the neurons had vacuolic dystrophy, and in some cases apoptosis are observed. There were compensatory regeneration processes in the ganglion cells of the group IV. They were characterized by: hypertrophy of the granular endoplasmic reticulum and an increase in the surface of the attached ribosomes; restoration of fine-grained neuroplasm of moderate electron density; and the appearance of new electron-density mitochondria in the perikaryon with densely packed crystals. The nuclei of round-shaped ganglion cells had diffusely located granules of euchromatin.

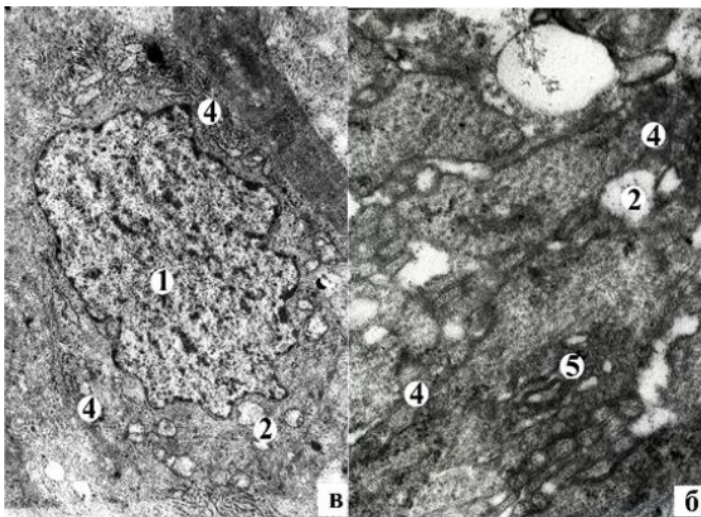


Figure 7: Compensatory and regenerative processes in retinal GCL of IV subgroup of rabbits after a month of treatment. Electronic microphotographs. Coll.: a, c, d) 9600, b) 24000.

Notes: 1 - neuron nucleus, 2 - vacuoles, 3 - neurofilaments, 4 - granular endoplasmic reticulum, 5 - Golgi complex, 6 - myelin-like inclusions.

In the the III and IV group (Figure 8) animals there were regenerative processes that were morphologically manifested at the ultrastructural level in light NC of *SN's hypothalamus*. The volumetric density of NG in the light NC were significantly increased in the animals of the group III - $3,11 \pm 0,18\%$ ($P < 0,05$) and in the animals of group IV - $4,27 \pm 0,29$ ($P < 0,01$) in comparison with the animals without treatment.

These data remained statistically lower than in the intact rabbits (in all cases $P > 0,05$). It should be noted that the volumetric density of NG in the group IV animals was significantly higher than in the group III ($P < 0,05$) animals. This could be an indirect suggestion for an intensive activation of the neurosecretory process due to the combined treatment using PES, in comparison with monotherapy with corticosteroids.

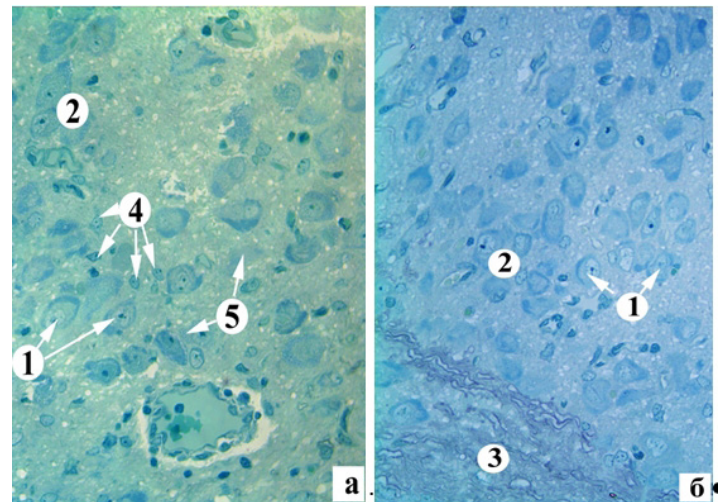


Figure 8: Histostructure of NS 30 days after treatment of III (a) and IV (b) subgroups. Semi-thin slice, painted methylene blue.

Symbols: 1 - normochromic neurons with central chromatolysis, 2 - normochromic neurons, 3 - visual junction, 4 - gliocytes, 5 - shadow cells.

Recovery processes were also observed in the dark NC. There was an increase in volumetric density of NG in the dark NC while compared with the animals without treatment, in the group III animals - $1,40 \pm 0,13\%$ ($P < 0,01$), in group IV animals - $1,71 \pm 0,17$ ($P < 0,003$), But these data remained statistically lower than in the intact rabbits (in all cases $P > 0,05$). It should be noted that the volume density of NG in the group IV animals was significantly higher than in those of group III ($P < 0,01$), which also confirms a more pronounced activation of neurosecretory processes under the influence of combined treatment with the use of PES, than with the monotherapy with corticosteroids. The "pynomorphic" neurons were observed along with the dark NCs within the regeneration processes. They were at the final stages of their life cycle [4,5].

The above morphological changes in the structure of the hypothalamus occurred along with changes in the concentration of hormones in the blood. The content of cortisol decreased from $92,31 \pm 3,26 \mu\text{g/dl}$ to $11,79 \pm 0,12 \mu\text{g/dl}$ ($P < 0,05$) in the group II animals while compared to group I animals. The content of ACTH decreased from $11,64 \pm 0,43 \text{ pg/ml}$ to $6,91 \pm 0,09 \text{ pg/ml}$ ($P < 0,05$) in the group II in comparison to group I animals. The cortisol's level increased to $290,12 \pm 6,72 \mu\text{g/dl}$ and the ACTH values decreased to $0,32 \pm 0,13 \text{ pg/ml}$ ($P < 0,05$) in group III compared with group I of the animals. The cortisol level was reduced to $6,93 \pm 0,14 \mu\text{g/dl}$ in group IV as compared to groups I-III ($P < 0,05$). The ACTH level in group IV ($6,13 \pm 0,12 \text{ pg/ml}$) was higher than in group III ($P < 0,05$) animals.

Discussion

In the retina of rabbit eyes after traumatic optic nerve crush, we observed dystrophic and destructive changes, which were mainly in the neurons of the INL, GCL and in nerve fibers of the NFL.

These are reactive axonal changes in the ganglion cells. Bipolar cells have vacuolic dystrophy due to disturbed blood supply to the retina.

In the same time, reactive edema and destructive changes were observed in the suprachiasmatic nucleus of the hypothalamus. This may cause decreased production of corticosteroids. Among the dark NCs there are cells with pronounced destructive changes that do not contain NG, but only lysosomes. Several authors relate these hypothalamic neurons to pycnomorphic cells that are in their final stage of their life cycle [2,3]. Their characteristic feature is high osmophilia and a total shrinkage of the cells in general. Others, and us, presume that they are isolated in the population of dark neurons and are "chromatophilic" and not "pycnomorphic" [4,5]. The chromatophilic neurons are characterized by a high level of RNA in the nucleus and nucleoli, and the absence of irreversible destructive changes, from which the authors conclude that these cells are more functionally active. The pycnomorphic neurons are in their final stage of cellular destruction. Like other researchers [4,5], we tend to attribute these neurons to be functionally active, and characterized by a high level of RNA in the nucleus and nucleoli, and without irreversible destructive changes. These authors also conclude that these cells are more functionally active than the light ones, but according to our research, the volumetric density of NG in light cells is significantly higher than that of dark ones.

In our research the combined treatment led to a partial restoration of the morphological parameters in the ipsilateral retina. The neuroprotective therapy contributed to the development of regenerative processes in the nucleus, more pronounced in combination with PES than with corticosteroid monotherapy, causing pronounced changes in the architecture of the retina and hypothalamus. These changes included increase in the number of neurosecretory granules, which can be a morphological sign of the activation of the neurohumoral process. We suggest that the optimal treatment of traumatic optic neuropathy with the use of phosphine electrostimulation leads to a compensatory regenerative process, also described by other authors [16-19]. This regenerative process is characterized by reduction of the thickness of the retina, restoration of cytokeratometric indices and a regenerative process in the bipolar and ganglion cells.

The blood ACTH level decreased while the cortisol level increased in the group III animals because of the megadose injection of corticosteroids. This is likely to result from a disturbance of the feedback between the hormones. This could also be a sign of the depletion of the production of the suprachiasmatic nucleus of the hypothalamus, which is confirmed by the presence of pycnomorphic neurons that are not capable to produce hormones. The content of the hormones is obviously observed in the group II of the animals in our experiment. Several authors have pointed out such a rearrangement of the hypothalamic NC under different pathological conditions [1, 2,13].

Conclusion

The retino-hypothalamic neurohumoral dysfunction is an important pathological mechanism in traumatic optic neuropathy. Contralateral phosphine electric stimulation leads to activation of the neurosecretory processes of the suprachiasmatic nucleus of the hypothalamus and the normalization of the cortisol and ACTH levels in rabbits, which may ensure the development of restorative processes in a more physiological condition than with megadose of corticosteroids, thus reducing their toxic effects and retaining retinal neuroprotective properties.

Ethical Statement

The experimental study was funding according to the suggestion of the Bioethics Commission and approved by the Ivano-Frankivsk National Medical University in 2016, № u20682016.

All procedures performed in studies involving animal participants were in accordance with the ethical standards of the institutional and/or national research committee and with the 1964 Helsinki declaration and its later amendments or comparable ethical standards.

References

1. Александрова ВА, Лебедев ВП, Рычкова СВ. Стимуляция эндорфинных структур мозга – новый немедикаментозный способ лечения. Журн неврологии и психиатрии им. СС Корсакова. 1996; 9: 101-103.
2. Булик РС. Ультраструктура нейронів супрахіазматичних ядер гіпоталамуса за умов світлової депривації. Електронний ресурс. Вісник наукових досліджень. 2008; 1: 78-80.
3. Zhurakivska OYa. Morphofunctional changes of arcuate nucleus of the hypothalamus at early stages of streptozotocin-induced diabetes. *Morfologiya*. 2013; 143: 16-22.
4. Zhurakivska OYa. The age features of morphological changes of the pituitary neurohypophysis system in the later stages of streptozotocin diabetes. *Journal World of Medicine and Biology*. 2014; 4: 123-127.
5. Kalymullyna LB. К вопросу о «темных» и «светлых» клетках. *Morfologiya*. 2012; 122: 75-80.
6. Levytskyi VA, Shovkova NI. Histoultrastructure of facial nerve in normal and under experimental neuropathy. *Vis-nyk morfologii*. 2009; 1: 38-43.
7. Moiseenko NM. Morpho functional aspects of restorative processes in the optic nerve after traumatic injury under the influence of high doses of corticosteroids. *J. ophthalmol. Ukraine*. 2015; 6: 37-41.
8. Сергеев ПВ. Рецепторы физиологически активных веществ. М Медицина. 1987.
9. Baver SB, Pickard GE, Patricia J. Sollars, et al. Two types of melanopsin retinal ganglion cell differentially innervate the hypothalamic suprachiasmatic nucleus and the olivary pretectal nucleus. *Eur J Neurosci*. 2008; 27: 1763-1770.

-
10. Bremer F. Photic responses of the basal preoptic area in the cat. *Brain Research*. 1976; 115: 145-149.
 11. Ferri GL. A Neurotrophin-Inducible Gene Expressed. *Trends Endocrinol Metab*. 1996; 7: 233-239.
 12. Li Y. Axon regeneration in goldfish and rat retinal ganglion cells differential responsiveness to carbohydrates and cAMP. *J Neurosci*. 2003; 23: 7830-7838.
 13. Said G, Baudoin D, Toyooka K. Sensory loss pains motor deficit and axonal regeneration in length-dependent diabetic polyneuropathy. *J Neurol*. 2008; 255: 1693-1702.
 14. Silke Kiessling, Patricia J. Sollars, Gary E. Pickard. Light Stimulates the Mouse Adrenal through a Retinohypothalamic Pathway Independent of an Effect on the Clock in the Suprachiasmatic Nucleus. *PLOS ONE*. 2014; 9: 1-11.
 15. Toshinai K, Nakazato M. Neuroendocrine regulatory peptide-1 and -2 novel bioactive peptides processed from VGF. *Cell Mol Life Sci*. 2009; 66: 1939-1945.
 16. Koji Toshinai, Hideki Yamaguchi, Haruaki Kageyama, et al. Neuroendocrine regulatory peptide-2 regulates feeding behavior via the orexin system in the hypothalamus. *Am J Physiol Endocrinol Metab*. 2010; 299: 394-401.